

# Successful Treatment of Atrophic Postoperative and Traumatic Scarring With Carbon Dioxide Ablative Fractional Resurfacing

## Quantitative Volumetric Scar Improvement

Elliot T. Weiss, MD; Anne Chapas, MD; Lori Brightman, MD; Christopher Hunzeker, MD; Elizabeth K. Hale, MD; Julie K. Karen, MD; Leonard Bernstein, MD; Roy G. Geronemus, MD

**Objective:** To assess the safety and efficacy of ablative fractional resurfacing (AFR) for nonacne atrophic scarring.

**Design:** In this before-and-after trial, each scar received 3 AFR treatments and 6 months of follow-up.

**Setting:** Private academic practice.

**Patients:** Fifteen women with Fitzpatrick skin types I to IV, aged 21 to 66 years, presented with 22 nonacne atrophic scars between June 1 and November 30, 2007. Three patients (3 scars) were excluded from the study after receiving 1 AFR treatment and not returning for follow-up visits. The remaining 12 patients (19 scars) completed all 3 treatments and 6 months of follow-up.

**Interventions:** Each scar received 3 AFR treatments at 1- to 4-month intervals.

**Main Outcome Measures:** Erythema, edema, petechiae, scarring, crusting, and dyschromia were graded after treatment and through 6 months of follow-up. Skin texture, pigmentation, atrophy, and overall appearance were evaluated after treatment and through 6 months of follow-up by the patient and a nonblinded investigator.

A 3-dimensional optical profiling system generated high-resolution topographic representations of atrophic scars for objective measurement of changes in scar volume and depth.

**Results:** Adverse effects of treatment were mild to moderate, and no scarring or delayed-onset hypopigmentation was observed. At the 6-month follow-up visit, patient and investigator scores demonstrated improvements in skin texture for all scars (patient range, 1-4 [mean, 2.79]; investigator range, 2-4 [mean, 2.95]), pigmentation for all scars (patient range, 1-4 [mean, 2.32]; investigator range, 1-4 [mean, 2.21]), atrophy for all scars (patient range, 1-4 [mean, 2.26]; investigator range, 2-4 [mean, 2.95]), and overall scar appearance for all scars (patient range, 2-4 [mean, 2.89]; investigator range, 2-4 [mean, 3.05]). Image analysis revealed a 38.0% mean reduction of volume and 35.6% mean reduction of maximum scar depth.

**Conclusion:** The AFR treatments represent a safe, effective treatment modality for improving atrophic scarring due to surgery or trauma.

*Arch Dermatol.* 2010;146(2):133-140

**A**TROPHIC SCARRING OCCURRING after surgical procedures or trauma is a common cosmetic problem for patients. Atrophic scars, which present as topographical depressions, result when dermal collagen and connective tissue production during the physiologic wound-healing process inadequately compensate for the tissue loss present after injury. Wound tension, tissue apposition, individual variations in wound healing, and scar contraction are all factors that contribute to the creation of a depressed, atrophic scar. With varying success, numerous ablative, nonablative, and fractional devices have been used to stimu-

late neocollagenesis and dermal remodeling in an attempt to improve the appearance of atrophic scars.

Carbon dioxide (CO<sub>2</sub>) lasers have been successfully used for many years to treat surgical, atrophic, and acne scars.<sup>1,2</sup> High-energy short pulses from the 10 600-nm CO<sub>2</sub> laser rapidly vaporize water, intracellularly and extracellularly, which creates precise levels of tissue ablation and minimizes extraneous dermal injury and scarring.<sup>3,4</sup> Resurfacing with the CO<sub>2</sub> laser ablates and smoothes the skin surface to precise tissue depths, and the deeper thermal coagulation of the dermis drives robust remodeling and neocollagenesis, which correspond to clinical improvement in atrophic scars.<sup>5</sup>

**Author Affiliations:** Laser & Skin Surgery Center of New York, New York, New York.

Although effective in improving scar appearance, CO<sub>2</sub> laser resurfacing generates significant tissue damage and therefore carries higher risks of adverse effects. After facial resurfacing, the average time to reepithelialization is at least 5 to 7 days, and the postprocedure erythema generally lasts 4 to 8 weeks, depending on the depth of ablation and extent of thermal injury.<sup>6,7</sup> This prolonged recovery often prevents patients from resuming normal activities in a timely manner. Other potential transient adverse effects include edema, oozing, milia, crusting, pain, acne flares, and pruritus. More serious adverse effects include bacterial infection, viral reactivation, scarring, and immediate or delayed permanent pigmentary alteration. Delayed-onset hypopigmentation is a well-documented adverse effect of CO<sub>2</sub> laser resurfacing, and this effect detracts from the overall cosmetic outcome and significantly lowers patient satisfaction.<sup>8</sup> The risky adverse effect profile and prolonged recovery period deter many physicians from using CO<sub>2</sub> laser resurfacing for scar revision.

The advent of fractional photothermolysis (FP) revolutionized the field of laser surgery by delivering light energy in a unique beam pattern.<sup>9</sup> Nonablative FP uses erbium-doped 1550-nm laser light to create columns of tissue coagulation in a pixilated pattern (also known as microthermal zones [MTZs]) just below the skin surface. These MTZs are separated by healthy, untreated tissue and protected by an intact overlying epidermis. Density and depths of MTZs can be modified according to the desired clinical result. The presence of an intact overlying epidermis and healthy tissue surrounding each MTZ results in rapid healing and significantly shortened recovery time.<sup>10</sup> The most commonly observed posttreatment adverse effects of FP are transient and mild and include erythema, edema, dryness, pruritus, and bronzing.<sup>11,12</sup>

With nonablative FP, despite the lack of tissue ablation, scarring can be moderately improved with a series of treatment sessions.<sup>13</sup> An ablative 30-W CO<sub>2</sub> laser (Fraxel Re:pair laser; Solta Medical, Hayward, California) combines CO<sub>2</sub> laser ablation with an FP system in a treatment known as ablative fractional resurfacing (AFR). A pixilated pattern of microscopic ablative wounds surrounded by healthy tissue is delivered to the skin,<sup>14</sup> and this combines the enhanced efficacy of tissue ablation with the shorter healing times and improved safety of FP technology. The AFR treatment avoids widespread epidermal coagulation while generating zones of tissue ablation and thermal coagulation much deeper than those seen with traditional ablative resurfacing. Deep zones of ablation and coagulation produce robust dermal remodeling, tissue tightening, neocollagenesis, and, ultimately, clinical improvement in atrophic scarring.

Treatment with AFR was previously demonstrated to safely improve the appearance of atrophic acneiform scarring<sup>15</sup> by reducing the depth of individual scars. In this prospective study, we evaluated the efficacy of AFR in the treatment of atrophic surgical and traumatic scars. An optical profiling system (Primos Imaging; GFM; Tetlow, Germany) allows high-resolution topographical imaging of cutaneous scars and calculation of quantitative volumetric and depth changes in atrophic scar volumes before and after treatment.<sup>16</sup>

Our patient population consisted of 15 enrolled women with Fitzpatrick skin types I through IV, aged 21 to 66 years, who presented with 22 nonacne, atrophic scars between June 1 and November 30, 2007. Potential patients were excluded on the basis of active infections or cancer, a history of keloid formation, allergies to lidocaine, isotretinoin use within the past 12 months, smoking, connective tissue disease, pregnancy, or cosmetic procedures in the treatment area within 12 months of enrollment. In this single-center study, all treatments were performed by the physician investigators according to the study protocol. Informed consent was obtained from each patient before treatment during this institutional review board–approved study. Three enrolled patients (3 scars) did not return for follow-up visits after the first AFR treatment, and they were excluded from the study. The remaining 12 patients with 19 atrophic scars received 3 AFR treatments for each scar at 1- to 4-month intervals and participated in follow-up through 6 months after the final treatment. Patients returned for evaluation 1 month after treatment, and subsequent treatments were delayed if moderate to severe erythema was noted at the treatment area. The presence of mild erythema is not a contraindication for subsequent treatment, and additional treatments were performed if mild erythema was noted at 1 month. **Table 1** displays the location, etiology, duration, prior treatments, and treatment settings for each scar. Eight patients underwent treatment on 1 scar, and 2 patients each had 2 scars treated. One patient had 3 scars and another had 4 scars treated in the study. Most of the enrolled scars (16 of 19) were the result of surgical procedures, but 3 scars from 2 patients were due to traumatic injury. Most of the enrolled scars (14 of 19) were located on the face, with the remaining located on the neck (1), upper extremity (1), and upper trunk (3).

Prophylactic valacyclovir hydrochloride (Valtrex; Glaxo-SmithKline, Research Triangle Park, North Carolina) was administered to 4 patients before treatment during the study because of the proximity of the treated scar to the perioral region. Fifteen minutes before the treatment, each scar was wiped with a pad containing alcohol, 70%, and anesthetized with a combination of subcutaneous lidocaine hydrochloride, 1%, and 1:100 000 epinephrine. One patient with extensive traumatic scars to her cheeks received oxycodone hydrochloride plus acetaminophen orally and ketorolac tromethamine intramuscularly before the treatment.

All treatments were performed with a prototype laser system (Fraxel Re:pair) using a fixed spot size of 120  $\mu\text{m}$ . Each treatment area included the entire scar and the skin immediately surrounding the scar. Pulse energies ranged from 20 to 100 mJ per pulse. Densities ranged from 100 to 300 MTZ/cm<sup>2</sup> per pass, with 1 to 3 passes per treatment area for a final density of 100 to 900 MTZ/cm<sup>2</sup>. The treatment settings listed in Table 1 have been converted to the percentage of coverage to correspond to the production model of the treatment laser. The energy delivered to each 0.5 cm<sup>2</sup> of scar ranged from 0.01 to 0.03 kJ depending on treatment settings. The rolling hand piece used to deliver the laser energy adjusts to the speed at which the operator moves, so each pass delivers the same energy and spot density per area covered.

Posttreatment erythema, edema, petechiae, scarring, pinpoint bleeding/crusting, and dyschromia were graded (on a scale of 0-3) by investigators at 3, 7, and 30 days after each treatment and at 1, 3, and 6 months after the final treatment. Investigators also recorded any other adverse event noted during each patient visit.

Improvements in the quality of skin texture and pigmentation, degree of skin atrophy, and overall appearance were graded on a quartile scale (0 indicates no improvement; 1, 1%-

**Table 1. Summary of Treated Scars<sup>a</sup>**

Patient No.	Scar Location	Cause	Scar Duration	Prior Treatment	Tx Settings, mJ per Pulse/% Coverage <sup>b</sup>
1	Chest	Surgical	11 y	None	40/30, 40/30, 40/21
	Breast	Surgical	3 y	None	40/30, 40/30, 30/29
2	Breast	Surgical	7 y	None	40/21, 20/11, 30/9
	Cheek	Surgical	2.5 y	None	70/20, 70/20, 70/27
3	Arm	Surgical	1 y	None	70/20, 70/20, 70/27
	Chin	Surgical	3 y	None	40/30, 40/30, 40/30
	Chin	Surgical	1 y	None	70/20, 70/20, 70/27
4	Cheek	Surgical	>6 mo	None	70/38, 70/38, 70/38
	Cheek	Surgical	>6 mo	None	70/38, 70/38, 70/38
	Chin	Surgical	>6 mo	None	70/38, 70/38, 70/38
5	Nose	Surgical	>6 mo	None	100/26, 70/38, 70/38
6	Cheek	Traumatic	>2 y	Single Tx with Fraxel Re:pair laser 2 y earlier	70/39, 70/39, 70/39
	Cheek	Traumatic	>2 y		70/39, 70/39, 70/39
7	Nose	Surgical	>3 y	Single Tx with CO <sub>2</sub> laser 2 y earlier	40/30, 40/30, 50/33
8	Cheek	Traumatic	19 y	None	70/38, 70/38, 70/38
9	Forehead	Surgical	>6 mo	None	70/27, 70/27, 70/27
10	Cheek	Surgical	>1 y	2 Tx with Fraxel Re:pair laser 1 y earlier	40/30, 70/38, 70/38
11	Upper lip	Surgical	4 y	None	70/38, 70/38, 70/38
12	Neck	Surgical	10 y	None	40/30, 40/30, 40/37

Abbreviations: CO<sub>2</sub>, carbon dioxide; Tx, treatment.

<sup>a</sup>Twelve patients with 19 scars completed 3 ablative fractional resurfacing treatments and 6 months of follow-up after the final treatment.

<sup>b</sup>Data are given for Tx 1, 2, and 3, respectively.

25% improvement [mild]; 2, 26%-50% improvement [moderate]; 3, 51%-75% improvement [marked]; and 4, 76%-100% improvement [very significant]) by patients and investigators after each treatment and at 1, 3, and 6 months after the final treatment. Objective measurements of scar volume and maximum depth were achieved with the 3-dimensional optical profiling system (Primos Imaging), which generated a 30 × 40-mm high-resolution topographic representation of each atrophic scar. The 3-dimensional images of each treated scar were obtained before treatment and 6 months after the final treatment. For 5 scars, pretreatment and 6-month follow-up 3-dimensional images were precisely matched and aligned so that identical shapes could be drawn to mark the exact scar location in both images. With the use of the imaging software, the volume of the topographical depression within each marked scar area was calculated for pretreatment and follow-up images. The percentage of improvement in scar volume was calculated for each of the 5 scars. In addition, for these 5 scars, the maximum scar depth was calculated at baseline and at 6 months after treatment. The 3-dimensional images for the remaining 14 scars were of insufficient quality to allow precise alignment and accurate comparison; therefore, quantitative posttreatment depth and volume changes could not be calculated for those scars.

## RESULTS

### SAFETY

Twelve patients with 19 scars completed the 6-month follow-up visit after the final AFR treatment. Three patients (with 3 scars) did not return for follow-up visits after their first AFR treatment. For the remaining 12 patients who completed the study, the incidence and mean severity (mean score for involved patients) for erythema, edema, dyschromia, petechiae, and scarring are summarized for each patient visit in **Table 2**.

After treatment, immediate postprocedure erythema was noted. Erythema peaked at 72 hours after each treatment with mean scores ranging from 2.23 to 2.26, representing moderate to severe erythema. By 1 week after each treatment, erythema decreased to mild to moderate (1.27-1.40) severity. Four to 6 weeks after the second and third treatments, erythema severity was trace to mild (0.84-0.85). Three months after the final treatment, erythema had resolved completely in 10 of 12 patients (17 of 19 scars) and remained trace in 2 patients who received treatment to individual facial scars. By 6 months, the trace erythema resolved completely in these 2 patients. Trace erythema was noted in 1 patient (with 2 scars) at 6 months; however, no erythema was observed during this patient's 3-month follow-up examination. Overall, erythema tended to resolve more rapidly after the second and third treatments.

Mild to moderate (1.06-1.69) edema was routinely observed and peaked immediately after treatment. By 1 week after the first, second, and third treatments, edema had resolved in all but 2 patients (with 3 scars), 1 patient (with 4 scars), and 2 patients (with 3 scars), respectively. Mild edema was noted in only 1 scar at 4 to 6 weeks after treatment 1. By 4 to 6 weeks after treatments 2 and 3, the edema had resolved completely.

In 1 patient with type IV skin, mild to moderate hyperpigmentation of the treated area was noted after the first, second, and third treatments, but this resolved spontaneously and completely by 3 months after the third treatment. Three other patients with type II skin experienced episodes of transient hyperpigmentation that resolved spontaneously within 2 months. Two patients, one with type II and the other with type III skin, experienced mild to moderate hypopigmentation of the treated areas, but this resolved completely in both patients within

**Table 2. Incidence and Mean Severity Scores for Posttreatment Adverse Effects<sup>a</sup>**

Adverse Effects	Time After Tx 1				Time After Tx 2				Time After Tx 3					
	<1 h	72 h	1 wk	4-6 wk	<1 h	72 h	1 wk	4-6 wk	<1 h	72 h	1 wk	4-6 wk	3 mo	6 mo
Erythema														
Incidence	18/19	15/16	14/15	17/19	19/19	17/17	15/16	16/19	18/19	13/13	15/15	13/18	2/15	2/19 <sup>b</sup>
Mean severity	1.89	2.26	1.36	1.53	2.10	2.24	1.40	0.84	2.11	2.23	1.27	0.85	0.50	0.50 <sup>b</sup>
Edema														
Incidence	16/19	9/16	3/15	1/19	16/19	11/17	4/16	0/19	14/19	10/13	3/15	0/18	0/15	0/19
Mean severity	1.69	1.00	1.00	1.00	1.06	1.00	1.00	0	1.14	1.20	0.83	0	0	0
Dyschromia														
Incidence	ND	ND	ND	3/19	0/19	ND	ND	1/19	0/19	ND	ND	2/18	0/15	0/19
Mean severity	ND	ND	ND	1.33	0	ND	ND	2.00	0	ND	ND	1.00	0	0
Petechiae														
Incidence	3/19	5/16	2/15	ND	ND	1/17	2/16	ND	ND	3/13	2/15	ND	ND	ND
Mean severity	1.00	2.00	1.00	ND	ND	3.00	1.00	ND	ND	1.00	1.00	ND	ND	ND
Crusting/pinpoint bleeding, incidence <sup>c</sup>	7/19	7/16	5/15	0/19	9/19	7/17	1/16	0/19	11/19	9/13	3/15	0/18	0/15	0/19

Abbreviations: ND, not done; Tx, treatment.

<sup>a</sup>Measured as mean severity among involved patients. For severity scores, 0 indicates absent; 0.5, trace; 1, mild; 2, moderate; and 3, severe. No scarring or permanent pigmentary changes were observed during follow-up.

<sup>b</sup>One patient with 2 scars exhibited no erythema at 3 months, but trace erythema was reported at 6 months.

<sup>c</sup>Only the presence or absence of crusting/pinpoint bleeding was recorded.

**Table 3. Mean Improvement Scores for Patient and Investigator Evaluations<sup>a</sup>**

	1 mo				
	After Tx 1	After Tx 2	After Tx 3	3 mo After Tx 3	6 mo After Tx 3
Skin texture					
Patient	1.50	2.47	2.66	2.31	2.79
Investigator	2.05	2.58	2.83	3.13	2.95
Pigmentation					
Patient	0.58	1.42	1.94	2.23	2.32
Investigator	0.68	2.16	2.11	2.80	2.21
Atrophy					
Patient	1.84	2.00	2.78	2.38	2.26
Investigator	2.16	2.75	3.06	3.27	2.95
Overall appearance					
Patient	1.82	2.76	2.83	3.15	2.89
Investigator	2.16	2.75	3.05	3.13	3.05

Abbreviation: Tx, treatment.

<sup>a</sup>For improvement evaluations, 0 indicates none; 1, mild (1%-25%); 2, moderate (26%-50%); 3, marked (51%-75%); and 4, very significant (76%-100%). Improvement was noted by patients and investigators for all scars in all variables measured. Each successive treatment led to incremental improvements in each variable.

2 months. No pigmentary changes were observed in any scars at the 3-month or 6-month follow-up visits.

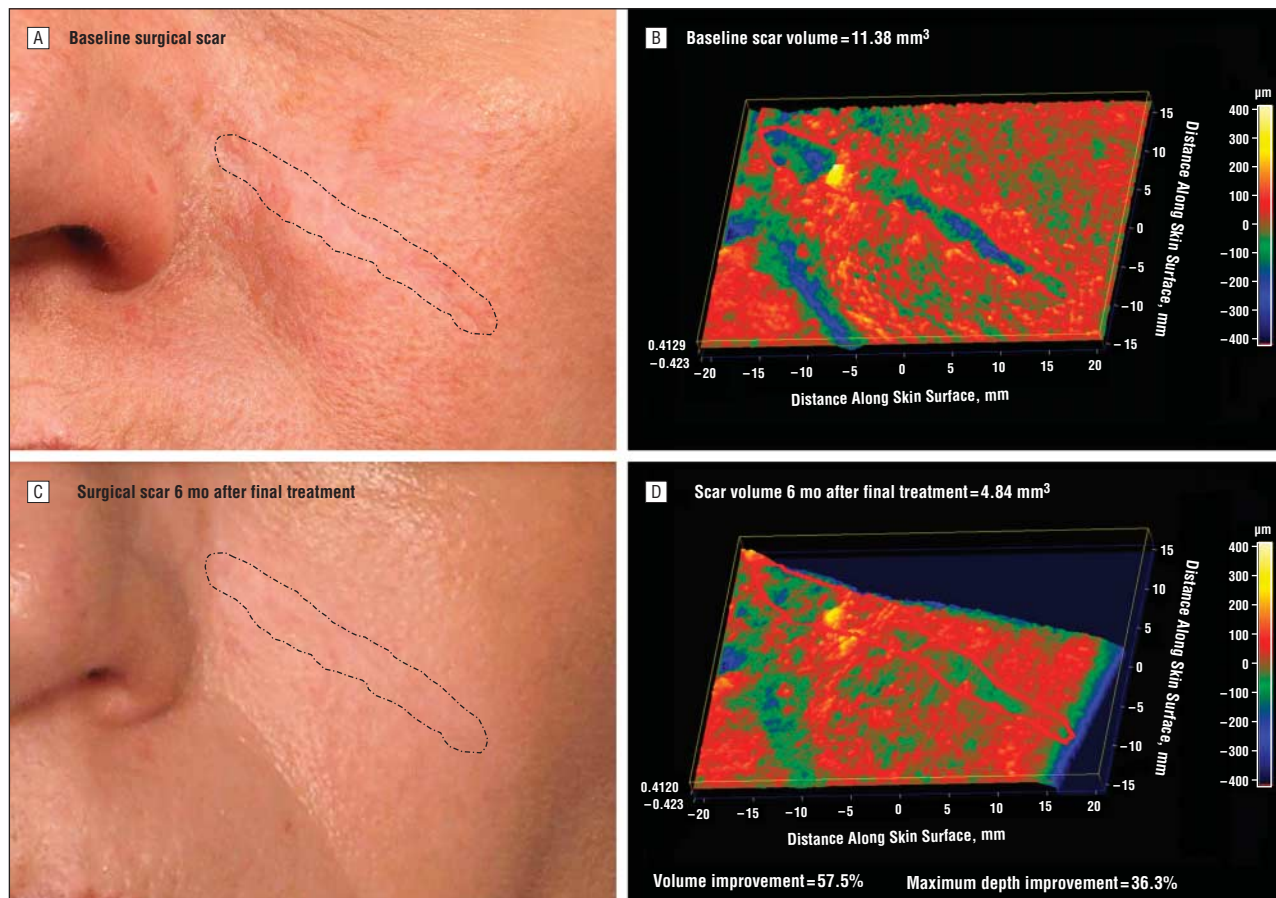
Postprocedure petechiae resolved in all but 2 patients by 1 week after each of the 3 treatments, and no petechiae were present at the 4- to 6-week follow-up examinations. Crusting/pinpoint bleeding resolved by 1 week in most of the patients, and only focal crusting remained in less than half of the patients. By 4 to 6 weeks after treatment, no crusting/pinpoint bleeding was observed. No treatment-induced scarring was observed throughout the study period. No bacterial infections or episodes of viral reactivation occurred during the study.

### EFFICACY

**Table 3** provides the mean patient and investigator scores of improvement in skin texture, pigmentation, atrophy, and overall appearance. Improvement was observed in all scar

variables after the first treatment, and subsequent treatments resulted in incremental improvement in all variables. For treated scars, maximal benefit was appreciated 3 to 6 months after the final treatment.

Mean patient (1.50) and investigator (2.05) scores for skin texture improvement at 1 month after treatment 1 correlated with 1% to 25% and 26% to 50% improvement, respectively. The patient and investigator scores rose after each subsequent treatment, and the 6-month mean patient (2.79) and investigator (2.95) scores both correlated with a 26% to 50% improvement in skin texture. After treatment 1, pigmentation scores for patients (0.58) and investigators (0.68) correlated with a 1% to 25% improvement. Scores improved with further treatments, and the 6-month mean patient (2.32) and investigator (2.21) scores correlated with a 26% to 50% improvement in scar pigmentation (improvement in hypopigmentation). One month after the first treatment, the mean patient (1.84) and investigator (2.16) scores



**Figure 1.** Baseline and 6-month posttreatment images of a surgical scar. A, Baseline photograph (dotted and dashed black outline). B, Baseline topographical image. Green areas within the solid red outline represent areas of depressions; the blue areas represent the areas of greatest depression (depth). C, Posttreatment photograph of the surgical scar (dotted and dashed black outline). D, Posttreatment topographical image. The decreased green and blue areas within the red line represent a 57.5% reduction in scar volume and a 36.3% reduction in maximum depth.

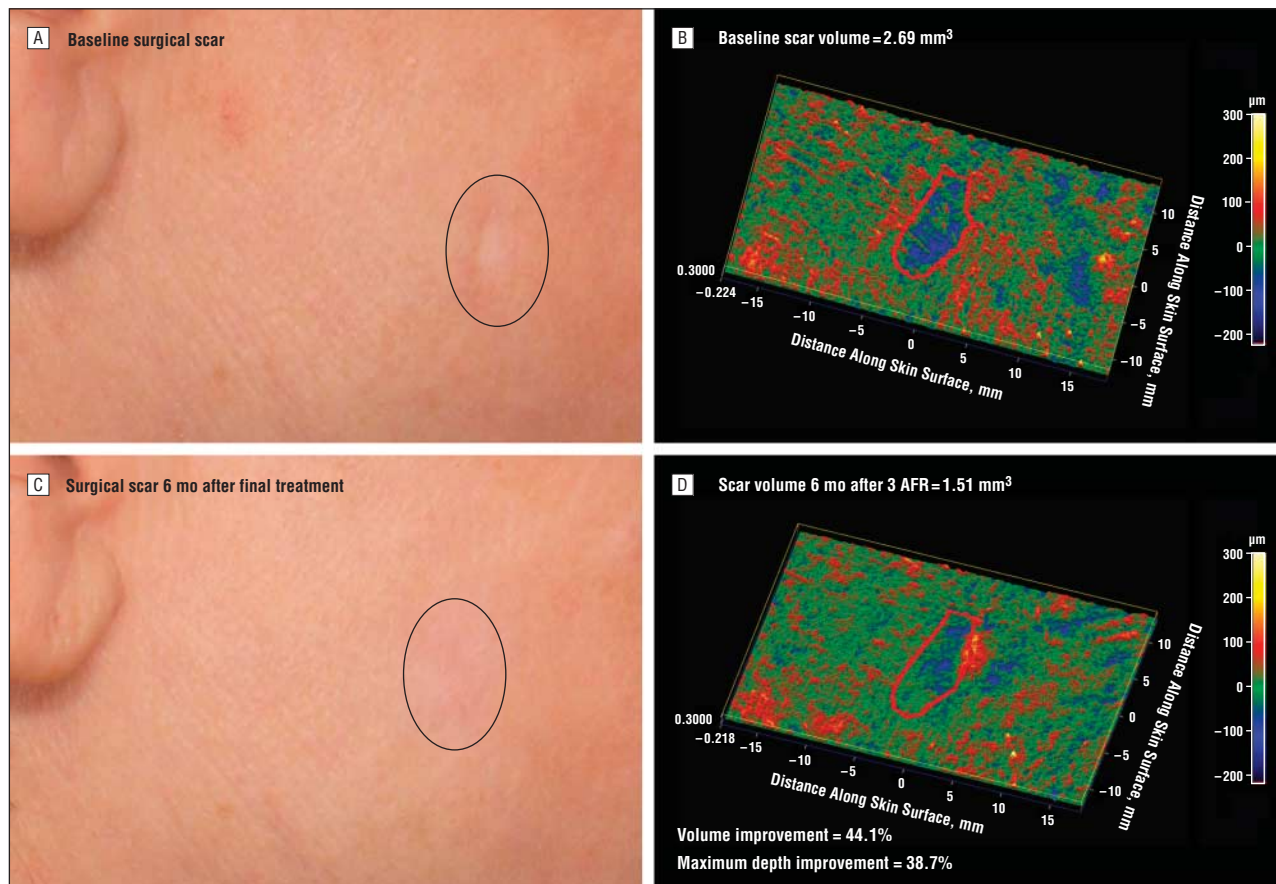
for skin atrophy correlated with 1% to 25% and 26% to 50% improvement, respectively. For all subsequent follow-up visits, the mean patient scores remained in the 26% to 50% improvement range. At 1 and 3 months after the final treatment, the mean investigator scores (3.06 and 3.27, respectively) for skin atrophy correlated with a 51% to 75% improvement, but the mean score (2.95) decreased slightly at the 6-month follow-up visit and correlated with a 26% to 50% improvement. At the final 6-month visit, patients rated 12 of their 19 scars (63%) as achieving a 51% or greater improvement, with 8 of 19 (42%) receiving ratings of 76% to 100% improvement in overall appearance. At this visit, investigators rated 17 of the 19 scars (89%) as achieving a 51% or greater improvement, with 3 of 19 scars (16%) receiving ratings of 76% to 100% improvement in overall appearance.

Subjective investigator and patient ratings of improvement correlated with objective measures of improvement generated from the topographical skin imaging. Three-dimensional topographical images were taken of scars before treatment and after completion of the treatment series. **Figure 1** and **Figure 2** each show a baseline and 6-month follow-up photograph of a treated scar; adjacent to each photograph is the baseline and 6-month follow-up topographic image corresponding to the adjacent photograph. For the topographic image in

Figure 1D, the improvement in the treated scar is depicted by the decreased green and blue areas within the outlined scar. For the topographical image in Figure 2D, volume improvement is represented by the decrease in blue areas within the outlined posttreatment scar. With the use of the image analysis software, identical lines were drawn around the baseline and posttreatment scars, and the volume of each scar was calculated. From these measured scar volumes we calculated the percentage of change in scar volume from baseline to the 6-month follow-up visit. The percentage of improvement in scar volume was determined for 5 scars using this method. **Table 4** shows that the percentage of volume improvement in these 5 scars ranged from 26.8% to 57.5%, with a mean improvement in scar volume of 38.0%. The maximum depths of these 5 scars were also calculated at baseline and at the 6-month follow-up visit, and the percentage reduction in maximum scar depth ranged from 26.3% to 40.9%, with a mean reduction of 35.6% (Table 4).

#### COMMENT

This is, to our knowledge, the first prospective study demonstrating the effectiveness of AFR treatments for atrophic postsurgical and traumatic scars. Our data suggest



**Figure 2.** Baseline and 6-month posttreatment images of a surgical scar. A, Baseline photograph (black outline). B, Baseline topographical image with the scar outlined in red. Blue areas represent areas of depression. C, Posttreatment photograph (black outline). D, Posttreatment topographical image. The decreased blue area within the red line represents a 44.1% reduction in scar volume and a 38.7% reduction in maximum depth.

**Table 4. Primos Imaging Scar Analysis<sup>a</sup>**

Reduction	Surgical Scar				Traumatic Scar, Right Cheek
	Left Cheek	Left Upper Arm	Right Cheek	Upper Lip	
Volume, % <sup>b</sup>	57.5	34.3	44.1	26.8	27.2
Depth, % <sup>c</sup>	36.3	26.3	38.7	40.9	36.0

<sup>a</sup>Analyses were performed using a commercially available optical profiling system (Primos Imaging; GFM; Tetlow, Germany).

<sup>b</sup>Ablative fractional resurfacing treatments reduced the scar volumes in surgical and traumatic scars, with a mean volume reduction of 38.0%.

<sup>c</sup>Ablative fractional resurfacing treatments reduced the maximum depths of surgical and traumatic scars, with a mean depth reduction of 35.6%.

that AFR is a safe and efficacious treatment for atrophic scars on and off the face, although a small number of off-face scars were treated in this study. All included scars received 3 AFR treatments at 1- to 4-month intervals and were followed up for 6 months after the final treatment. For the energy fluences used in this study (20-100 mJ), dermal penetration ranged from approximately 600 to 1700  $\mu\text{m}$  in depth. For facial scars, our most commonly used treatment settings were generally 70 mJ per pulse, 200 MTZ/cm<sup>2</sup> per pass, and 2 to 3 passes per treatment (27%-38% coverage). For off-face scars, the laser settings were generally 40 mJ per pulse, 200 MTZ/cm<sup>2</sup> per pass, and 2 to 3 passes (20%-30% coverage). However, our subsequent extensive clinical experience with AFR for off-face scarring suggests that higher fluences result in prolonged erythema of treated areas. This prolonged

treatment site erythema becomes a cosmetic concern for many patients, and we frequently choose lower fluences to shorten posttreatment erythema. For off-face scarring, higher fluences create deeper ablation and therefore may produce more tissue remodeling and clinical improvement. Although possibly less efficacious, we obtain favorable results using lower fluences for off-face sites, and patients prefer this trade-off to shorten the duration of posttreatment erythema.

Our experience suggests that proper technique allows densities of 30% to 50% coverage and 20% to 30% coverage to be safely used routinely on and off the face, respectively. We believe that higher levels of coverage yield optimal clinical results for scarring. For off-face scars, however, increasing densities lead to prolonged erythema that is much greater than for facial scars. For this

reason, we often choose lower densities and lower energy fluencies for off-face scars to minimize the duration of erythema. Patients often prefer this trade-off to minimize posttreatment erythema.

Both the patients and the investigators noted improvements in all scar variables evaluated. At the 6-month follow-up, the mean patient and investigator scores correlated with a 26% to 50% improvement in scar atrophy, pigmentation, and texture. For the category of overall improvement, the mean 6-month patient scores correlated with a 26% to 50% overall improvement, and the mean investigator scores correlated with a 51% to 75% overall improvement. At 6 months, the patients and investigators rated 63% and 89% of scars, respectively, as achieving a 51% or greater overall improvement. Furthermore, 42% and 16% of the treated scars achieved a 76% or greater overall improvement according to 6-month patient and investigator scores, respectively. This impressive, uniform improvement across all scar variables is likely related to the ability of AFR to generate deep dermal ablation and coagulation to depths beyond those reached by traditional CO<sub>2</sub> laser resurfacing. Although not statistically significant, facial scars that were routinely treated at higher energy fluences (70 mJ per pulse) generally responded to a greater degree and had a more uniform response compared with off-face scars. This observation is likely related to the deeper levels of ablation and coagulation obtained with higher energy fluences. At higher fluences, tissue ablation and coagulation extend beyond 1 mm into the skin; this deep thermal effect may produce more robust dermal remodeling and collagen production.<sup>17</sup>

The objective topographical analysis of 5 individual scars substantiates the clinical observations reported by the patients and investigators. Our analysis demonstrated volumetric improvement in all of the 5 scars evaluated, with a range of 26.8% to 57.5% and a mean improvement of 38.0%. The maximum scar depth was reduced in all of the 5 scars evaluated, with a range of 26.4% to 40.9% improvement and a mean reduction of 35.6%. Clinical improvement after AFR is likely multifactorial; improvements in pigmentation, altered optical properties, enhanced collagen density, and decreased scar volume all likely contribute to overall appearance. This topographical analysis suggests that volume improvement, at least, is a significant contributing factor to clinical improvement.

During the 6-month follow-up, no incidents of delayed-onset hypopigmentation, permanent pigmentary alteration, or scarring were observed. Treatments were well tolerated by patients, and adverse effects were generally mild to moderate. Compared with conventional CO<sub>2</sub> laser resurfacing, AFR treatments provided a safer adverse effect profile, a more rapid healing period, and shorter downtimes for patients. Despite its much improved safety profile, AFR treatments resulting in scarring and ectropion have been reported in the literature.<sup>18</sup>

After traditional CO<sub>2</sub> laser resurfacing, delayed-onset hypopigmentation can be seen in more than 19.2% of patients<sup>8</sup>; however, no incidents of delayed pigmentary alterations were observed during our 6-month fol-

low-up after the third treatment. From the date of the first treatment to the final 6-month follow-up, patients were followed up for an average of approximately 10.5 (range, 8.5-13.0) months with no evidence of delayed pigmentary alteration. The preservation of healthy untreated skin between zones of thermal ablation likely explains the lack of delayed, permanent pigmentary problems after AFR treatment. Transient mild to moderate postinflammatory hypopigmentation/hyperpigmentation developed in less than half of the AFR-treated scars, but these pigmentary changes all resolved spontaneously by 3 months after the final treatment.

The treatment protocol was based on our prior experience with nonablative resurfacing and AFR treatments for acne scars. As we have observed previously, improvement follows the first treatment, and subsequent treatments lead to incremental improvements in scar appearance. Although treatment intervals varied from 1 to 4 months, patients generally reported that the oozing, crusting, and edema after the second and third treatments tended to be shorter and better tolerated. This phenomenon could be the result of a priming of the wound-healing response by the first treatment, but further research is needed to clarify this observation. Similar to results from our previous studies<sup>15</sup> and our personal experience, maximal benefit was seen 3 to 6 months after AFR treatment. Optimal intervals between treatments remain to be determined.

## CONCLUSIONS

Ablative fractional resurfacing with the use of a CO<sub>2</sub> laser enables the creation of deep dermal ablation and coagulation and minimizes patient downtime and the risk of serious adverse effects. A favorable adverse effect profile makes AFR an excellent choice for treating atrophic surgical and traumatic scars on the face and body. Objective topographical measures of scar volume and depth improvement substantiate and support the qualitative improvements reported by patients and investigators in this study. Further research into the most beneficial treatment intervals for scars on and off the face is needed. In addition, treatment settings for scars in darker skin types remain to be optimized.

**Accepted for Publication:** August 19, 2009.

**Correspondence:** Elliot T. Weiss, MD, Laser & Skin Surgery Center of New York, 317 E 34th St, New York, NY 10016 (eweiss@laserskinsurgery.com).

**Author Contributions:** Drs Weiss and Geronemus had full access to all the data in the study and take responsibility for the integrity of the data and the accuracy of the data analysis. *Study concept and design:* Weiss, Brightman, and Geronemus. *Acquisition of data:* Weiss, Brightman, and Geronemus. *Analysis and interpretation of data:* Weiss, Chapas, Hunzeker, Hale, Karen, Bernstein, and Geronemus. *Drafting of the manuscript:* Weiss and Geronemus. *Critical revision of the manuscript for important intellectual content:* Weiss, Chapas, Brightman, Hunzeker, Hale, Karen, Bernstein, and Geronemus. *Statistical analysis:* Weiss. *Administrative, technical, and material sup-*

port: Weiss and Geronemus. *Study supervision:* Weiss, Chapas, Brightman, Hunzeker, Hale, Karen, Bernstein, and Geronemus.

**Financial Disclosure:** Dr Chapas is a consultant for Solta Medical. Dr Geronemus is a shareholder in Solta Medical and serves on the advisory boards of Photomedex, Lumenis, Candela, Zeltiq, Skin Cancer Company, and Endymion.

**Funding/Support:** This study was supported by equipment (the prototype Fraxel Re:pair laser) from Solta Medical for use during the study.

**Role of the Sponsor:** The sponsor had no role in the design or conduct of the study; in the collection, analysis, or interpretation of the data; or in the preparation, review, or approval of the manuscript.

## REFERENCES

1. Bernstein LJ, Kauvar AN, Grossman MC, Geronemus RG. Scar resurfacing with high-energy, short-pulsed and flashscanning carbon dioxide lasers. *Dermatol Surg.* 1998;24(1):101-107.
2. Alster TS, West TB. Resurfacing of atrophic facial acne scars with a high-energy, pulsed carbon dioxide laser. *Dermatol Surg.* 1996;22(2):151-155.
3. Alster TS, Tanzi EL. Laser skin resurfacing: ablative and nonablative. In: Robinson J, Sengelman R, Siegel DM, Hanke CM, eds. *Surgery of the Skin*. New York, NY: Elsevier Science Inc; 2005:611-624.
4. Nanni CA, Alster TS. Complications of carbon dioxide laser resurfacing: an evaluation of 500 patients. *Dermatol Surg.* 1998;24(3):315-320.
5. Walia S, Alster TS. Prolonged clinical and histologic effects from CO<sub>2</sub> laser resurfacing of atrophic acne scars. *Dermatol Surg.* 1999;25(12):926-930.
6. Alster T, Zauyanov L, Zauyanov-Scanlon L. Laser scar revision: a review [published correction appears in *Dermatol Surg.* 2007;33(6):770]. *Dermatol Surg.* 2007;33(2):131-140.
7. Tanzi EL, Alster TS. Single-pass carbon dioxide versus multiple-pass Er:YAG laser skin resurfacing: a comparison of postoperative wound healing and side-effect rates. *Dermatol Surg.* 2003;29(1):80-84.
8. Bernstein LJ, Kauvar AN, Grossman MC, Geronemus RG. The short- and long-term side effects of carbon dioxide laser resurfacing. *Dermatol Surg.* 1997;23(7):519-525.
9. Geronemus RG. Fractional photothermolysis: current and future applications. *Lasers Surg Med.* 2006;38(3):169-176.
10. Manstein D, Herron GS, Sink RK, Tanner H, Anderson RR. Fractional photothermolysis: a new concept for cutaneous remodeling using microscopic patterns of thermal injury. *Lasers Surg Med.* 2004;34(5):426-438.
11. Fisher GH, Geronemus RG. Short-term side effects of fractional photothermolysis. *Dermatol Surg.* 2005;31(9, pt 2):1245-1249.
12. Graber EM, Tanzi EL, Alster TS. Side effects and complications of fractional laser photothermolysis: experience with 961 treatments. *Dermatol Surg.* 2008;34(3):301-307.
13. Alster TS, Tanzi E, Lazarus M. The use of fractional laser photothermolysis for the treatment of atrophic scars. *Dermatol Surg.* 2007;33(3):295-299.
14. Hantash BM, Bedi VP, Kapadia B, et al. In vivo histological evaluation of a novel ablative fractional resurfacing device. *Lasers Surg Med.* 2007;39(2):96-107.
15. Chapas AM, Brightman L, Sukal S, et al. Successful treatment of acneiform scarring with CO<sub>2</sub> ablative fractional resurfacing. *Lasers Surg Med.* 2008;40(6):381-386.
16. Friedman PM, Skover GR, Payonk G, Kauvar AN, Geronemus RG. 3-D in-vivo optical skin imaging for topographical quantitative assessment of non-ablative laser technology. *Dermatol Surg.* 2002;28(3):199-204.
17. Hantash BM, Bedi VP, Chan KF, Zachary CB. Ex vivo histological characterization of a novel ablative fractional resurfacing device. *Lasers Surg Med.* 2007;39(2):87-95.
18. Fife DJ, Fitzpatrick RE, Zachary CB. Complications of fractional CO<sub>2</sub> laser resurfacing: four cases. *Lasers Surg Med.* 2009;41(3):179-184.