

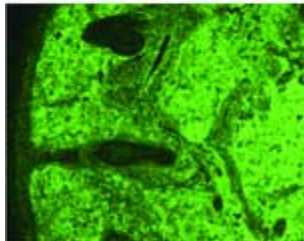
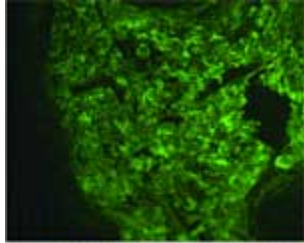
## Illuminating Idea

---

LED photomodulation offers novel, safe, nonablative approach to photoaging

January 1, 2003

By: Cheryl Guttman  
Dermatology Times



Chicago - Photomodulation of cellular activity induced by low-intensity illumination from light-emitting diodes (LED) appears to have promise for treating photoaging as well as a variety of other dermatologic problems, Robert A. Weiss, M.D., said at the annual meeting of the American Society for Dermatologic Surgery.

*Dr. Weiss (left) Dr. McDaniel (right)*

The LED-based photomodulation technique is a nonthermal treatment associated with no discomfort or tissue injury. It was developed by David H. McDaniel, M.D., assistant professor of clinical dermatology, Eastern Virginia Medical School in Virginia Beach, Va.

In initial in vitro studies, Dr. McDaniel found that by altering various parameters, he could use the narrow-band, noncoherent light emitted by LEDs to induce, inhibit, or have no effect on the activity of various skin cells.

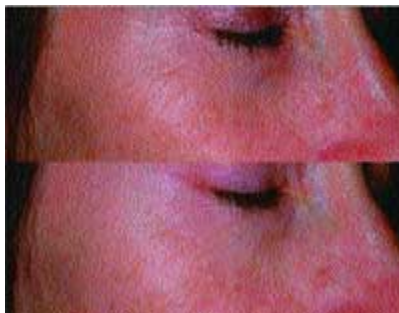Based on the finding that LED photomodulation could be used to stimulate collagen synthesis by cultured fibroblasts, clinical studies of photoaging were undertaken. The results of those trials confirm the effect of the treatment on collagen synthesis and show that it results in clinical benefits manifested by marked improvements in fine wrinkles and skin texture along with more modest effects on skin tone and the appearance of fine telangiectasia, reported Dr. Weiss, assistant professor of dermatology, Johns Hopkins University School of Medicine, Baltimore.

"The photomodulation treatment is extremely safe as it involves amazingly low energy levels. While its exact mechanisms of action are still under study, photomodulation appears to represent a completely novel concept for using light to treat photoaging. I think we can expect it to be part of the future of nonablative treatment for aging skin, but that it will also have much greater applications in dermatology," Dr. Weiss said.

In another ongoing study, photomodulation is under evaluation as a treatment for promoting wound healing. It was shown in a preliminary clinical trial to accelerate by 50 percent the rate of healing of wounds induced by a single pass with a CO2 laser.

Studies are also being planned to examine its potential for stimulating hair growth in men with male pattern baldness and women with hair loss. And because photomodulation can also be used to inhibit cellular activity, there is also interest in its application for limiting unwanted hair growth.

Mechanism-of-action studies are also under way. One working hypothesis for those investigations is that the photons delivered by the LEDs effect cell mitochondria activity.

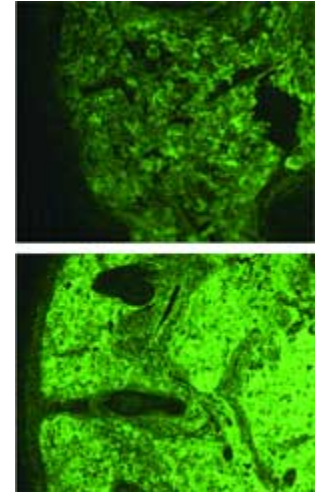


*Patient at baseline (top) and post LED photomodulation treatment.*

The clinical photoaging studies are being performed with a patent pending photomodulation device (Gentlewaves). The tabletop instrument features a panel of LEDs that illuminate the entire face as the patient sits in front of the light source with the chin resting in a holder. Treatment times have varied in the clinical studies conducted so far, but have been relatively short, typically less than 15 minutes.

"Photomodulation offers the opportunity to treat large areas of the skin in little time, and that appears to be another advantage of this approach compared with lasers," Dr. Weiss said.

Clinical investigation of photomodulation for photoaging began with pilot trials conducted by Dr. McDaniel. Those studies enrolled 47 patients and evaluated responses achieved with different LED settings. Overall, the treatment resulted in a 40 percent to 45 percent global



*Immunofluorescent skin biopsy of collagen at baseline (top) and one week after eight LED photomodulation treatments.*

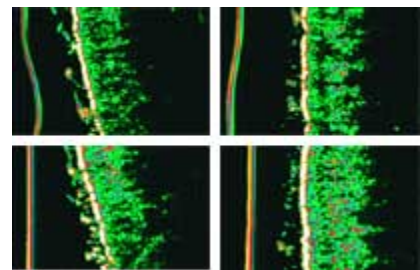
*(Photographs courtesy of David H. McDaniel, M.D.)*

improvement in wrinkles, skin tone, and texture. The best results were achieved in patients treated using parameter settings developed from studies of cell responses in tissue cultures, Dr. Weiss said.

Subsequently, a multicenter trial was undertaken by Dr. McDaniel with Dr. Weiss, his wife Margaret Weiss, M.D., and Roy Geronemus, M.D., New York, as co-investigators. That study enrolled 90 photoaged subjects who underwent a series of eight treatments using fixed settings. At one week after completing the photomodulation regimen, the investigator ratings showed improvements in skin roughness, elastosis, and pore size, as well as decreases in redness.

Reductions in fine wrinkles were noted in the periorbital region as well as around the mouth and were confirmed by digital profilometry studies, Dr. Weiss said.

Histological evaluation is being performed in 10 study subjects who are undergoing biopsies at baseline and at one, two, and three months post-treatment. Not all of the biopsies have been performed yet, but the preliminary results from conventional histology, and immunofluorescence studies show the photomodulation treatment resulted in new collagen, elastin and GAG formation in the upper levels of the dermis.



LED photomodulation at baseline (top two photos) and posttreatment (bottom two photos).

Given the ease and safety of photomodulation, Dr. Weiss said that one might anticipate seeing a number of LED-based devices introduced onto the market. However, he emphasized that achieving the desired response depends on proper modulation using proprietary protocols and it is possible that some devices will have no effect.

"Photomodulation therapy can be analogized to use of an infrared remote for controlling TV operation. The light signal from the remote can be pointed at the TV, but unless it is programmed with the right code for that particular set, it will have no effect. Similarly, one needs to have the right codes for the LEDs to achieve the desired effect on the targeted cells," Dr. Weiss said.

Dr. Weiss has a financial interest in the technology he discussed.