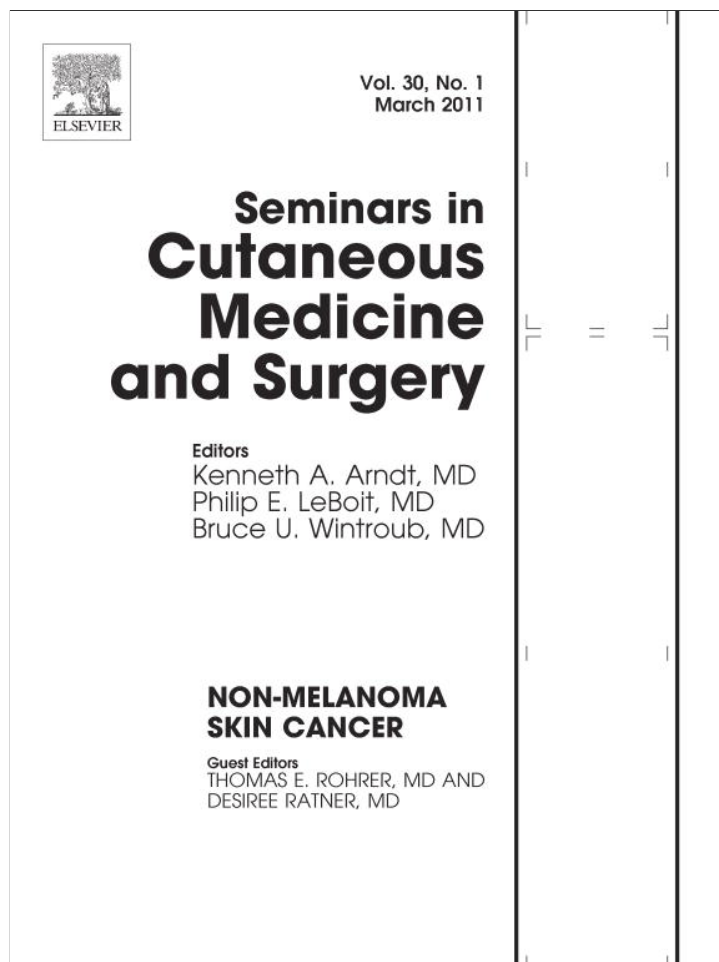

This article appeared in a journal published by Elsevier. The attached copy is furnished to the author for internal non-commercial research and education use, including for instruction at the authors institution and sharing with colleagues.

Other uses, including reproduction and distribution, or selling or licensing copies, or posting to personal, institutional or third party websites are prohibited.

In most cases authors are permitted to post their version of the article (e.g. in Word or Tex form) to their personal website or institutional repository. Authors requiring further information regarding Elsevier's archiving and manuscript policies are encouraged to visit:

<http://www.elsevier.com/copyright>



Do Lasers or Topicals Really Work for Nonmelanoma Skin Cancers?

Lori Brightman, MD,* Melanie Warycha, MD,[†] Robert Anolik, MD,* and Roy Geronemus, MD*

Novel strategies are urgently needed to address the millions of nonmelanoma skin cancers treated in the United States annually. The need is greatest for those patients who are poor surgical candidates or those prone to numerous nonmelanoma skin cancers and therefore at risk for marked disfigurement. Traditional treatment strategies include electrosurgery with curettage, radiation therapy, cryotherapy, excision, and Mohs micrographic surgery. Alternatives to traditional treatment, including topical medications and light or laser therapies, are becoming popular; however, there are various degrees of efficacy among these alternative tactics. These alternatives include topical retinoids, peels, 5-fluorouracil, imiquimod, photodynamic therapy, and lasers. The purpose of this paper is to review the available data regarding these alternative strategies and permit the reader to have a sense of which therapies are reasonable options for care.

Semin Cutan Med Surg 30:14-25 © 2011 Elsevier Inc. All rights reserved.

It has been well documented that the incidence of nonmelanoma skin cancer (NMSC) is increasing, of which approximately 75% of cases each year are attributed to basal cell carcinomas (BCCs) and 20% to squamous cell carcinomas (SCCs). On the basis of an analysis of the Medicare Total Claims Data Set and the National Ambulatory Medical Care Survey for the years 1992 and 1996-2006, the total number of NMSCs treated in the United States in 2006 was more than 2.1 million. Furthermore, there was a 14.3% increase in the number of persons with at least one procedure for NMSC from 2002 to 2006.¹ The rates in immunosuppressed populations are even greater, with retrospective studies documenting skin cancer development in 13% to 52% of transplant recipients, with incidence increasing with years of immunosuppression.²⁻⁵ The precipitous increase in NMSCs, especially in younger patient populations, could translate into an alarming number of NMSCs as the population ages. This progressive increase in the number of NMSCs highlights the need for multiple treatment options in addition to traditional surgical approaches.

According to data from the Medicare Current Beneficiary Study from 1992 to 1995, the total cost of nonmelanoma skin

cancer management was estimated to be \$426 million per year.⁶ If estimating costs for the general population, treatment of NMSCs has exceeded more than one billion dollars per year.⁷ This financial burden underlies the need for prevention education in addition to more economical treatment strategies.

Standard Treatment Modalities for Nonmelanoma Skin Cancer

Both surgical and nonsurgical treatment modalities for NMSC have been developed, with the common goal of achieving a high cure rate with minimal tissue destruction and an acceptable cosmetic result. Mohs micrographic surgery is considered the gold standard for the treatment of nonmelanoma skin cancer because it allows for the histologic assessment of peripheral and deep margins and has a 5-year recurrence rate of 1%-3.2% for primary basal cell cancer (up to 6.7% for recurrent BCCs) and 3%-5.9% for SCCs.⁸ This is in comparison with standard excision, with a recurrence rate of 5.3%-10.1% for BCCs (primary and recurrent) and up to 8% for SCCs.⁹⁻¹¹ Although cure rates with cryosurgery and electrodesiccation and curettage approach those of surgical excision, these techniques have an increased risk of pigment alteration and either hypertrophic or atrophic scarring.

Although the surgical approach for NMSC has rather low recurrence rates and is considered standard of care for many nonmelanoma skin cancers, there are circumstances in which

*Laser & Skin Surgery Center of New York, 317 East 34th Street New York, NY 10016.

[†]The Ronald O. Perelman Department of Dermatology, New York University, School of Medicine, New York, NY.

Address reprint requests to Lori Brightman, MD, Laser & Skin Surgery Center of New York. E-mail: lbrightman@laserskinsurgery.com

surgical alternatives are needed and a less invasive option is appropriate. Newer nonsurgical treatment modalities, including the use of topical pharmacotherapy, such as tazarotene, 5-fluorouracil (5-FU) and imiquimod, photodynamic therapy (PDT), and laser or light treatment will be the subject of this review.

Role of Alternative Treatment Modalities for Nonmelanoma Skin Cancer

There are many factors that need to be considered in selecting the most appropriate treatment modality in patients with NMSC. Patients deemed to be poor surgical candidates, patients those with NMSC imposing upon critical anatomical structures, or those in whom cumulative surgical procedures for diffuse disease will result in functional or cosmetic disfigurement (ie, patients with basal cell nevus syndrome) may benefit from noninvasive treatment options. Furthermore, the size of the lesion or the presence of multiple adjacent lesions could also be an indication for nonsurgical approaches as primary tumor treatment or as adjunct to reduce tumor burden. Patients may also prefer the ease of application of a topical regimen compared with surgery. Finally, the location of a lesion in an area of poor wound healing or in a cosmetically sensitive area may necessitate treatment with nonsurgical modalities.^{12,13}

Review of Topical Treatment Regimens for Nonmelanoma Skin Cancer

Tazarotene

The topical retinoid tazarotene has been theorized to mitigate the growth of tumor cells. A few small trials to date have examined its efficacy in the treatment of NMSC. Peris et al¹⁴ examined once daily application of tazarotene, 0.1% gel for 5-8 months in the treatment of BCCs and noted a 53% clearance rate, in addition to a 47% reduction in size for residual tumors. A larger randomized phase 2 trial sponsored by the National Cancer Institute to investigate topical tazarotene in the treatment of BCCs is currently ongoing. Treatment of SCC in situ (SCCIS) with topical tazarotene, 0.1% gel has also been investigated, with daily application for 6 months resulting in a 47% clearance rate in a study cohort of 15 patients. Of note, more than 30% of patients withdrew from this study because of adverse effects.¹⁵

Fluorouracil for Basal Cell Carcinoma

Topical 5-FU is approved by the Food and Drug Administration for the treatment of actinic keratoses and superficial BCCs. This chemotherapeutic agent inhibits thymidylate synthetase, thereby disrupting DNA synthesis in actively proliferating cells. Despite its treatment indications, there are surprisingly few studies evaluating the efficacy of 5-FU in the treatment of BCCs. In fact, in older studies, authors discuss

formulations of 5-FU that are not readily available, thus questioning the applicability of these data.¹⁶ As such, Gross et al¹⁷ set out to reevaluate the efficacy of 5-FU in BCCs in 2007 in an open-label study of twice-daily application of 5-FU for up to 12 weeks in 29 patients with 31 biopsy-proven superficial BCCs. With a mean treatment duration of 10.5 weeks, 28 of 31 (90%) lesions exhibited complete clearance upon surgical excision with good cosmetic outcome, thus substantiating prior results regarding the efficacy and tolerability of 5-FU in the treatment of superficial BCCs.

Fluorouracil for Squamous Cell Carcinoma In-Situ

Although the use of 5-FU has also demonstrated efficacy in the treatment of SCCIS, most of the data stems from case reports and open-label studies rather than randomized controlled trials. In a study by Bargman et al,¹⁸ the twice-daily application of 5-FU for up to 9 weeks, with repeat courses at the discretion of the treating physician, was evaluated in 24 patients with 26 cases of histologically proven SCCIS. Post-treatment biopsies were performed (time of biopsy not disclosed) in 18 of 26 lesions, 2 of which revealed residual SCCIS. Of the remaining lesions, 6 had clinically resolved and were not biopsied, and 2 were lost to follow-up, with the average duration of clinical follow-up noted to be 55.2 months. By using a dosing regimen of 5-FU daily for 1 week followed by twice daily for 3 weeks for 1 to 2 cycles, Salim et al¹⁹ demonstrated a complete clinical clearance in 22 of 33 (67%) cases of SCCIS at 6-weeks' follow-up. This was in comparison with an 88% clinical response after photodynamic therapy. At 1-year follow-up, 6 recurrences were documented in the 5-FU treatment group, thus lowering the overall response rate to 48%.

A similar dosing scheme was evaluated by Morton et al²⁰ in 2006 in which treatment of SCCIS with 5-FU (once daily for 1 week then twice daily for 3 weeks, up to 2 cycles) or cryotherapy (minimum freeze time of 20 s) was compared with 2 cycles of photodynamic therapy with methyl aminolevulinic acid (MAL) (prior curettage, incubation for 3 hours, red light 570-670 nm, 75 J/cm²). At 1 year posttreatment, the clinical complete response rate with 5-FU was 69% (20/29) on the basis of a per-protocol analysis, compared with an 80% response with methyl-aminolevulinic acid (MAL)-PDT and 67% response rate with cryotherapy. Thus, on the basis of available data, the response of SCCIS to treatment with 5-FU is poor, with a 48%-69% clearance rate at 1 year on the basis of a treatment regimen of once daily application for 1 week followed by twice daily application for 3 weeks.

Imiquimod for Basal Cell Carcinoma

Imiquimod, 5% cream (Aldara; Graceway Pharmaceuticals, Malvern, PA) was first approved by the Food and Drug Administration in 1997 for the topical treatment of external genital and perianal warts, and later for actinic keratoses and in 2004 for superficial BCCs. Imiquimod functions as an immune response modifier that binds to toll-like receptor 7 and induces transcription of interferon- α , interferon- γ , and

Table 1 Select Studies Addressing Imiquimod for BCC^{22-27,73}

	Sample Size	Dosing Regimen	Treatment Duration, wks	Time of Histologic Assessment, wks	Clearance Rate, %*
Superficial BCC					
Geisse et al	10	Twice a day	12	6	100
	31	Daily	12	6	87.1
	26	Daily 5 times/wk	12	6	80.8
	29	Daily 3 times/wk	12	6	51.7
Geisse et al 2004	179	Daily	6	12	79
	185	Daily 5 times/wk	6	12	82
Marks et al	3	Twice a day	6	6	100
	33	Daily	6	6	87.9
	30	Twice daily 3 times/wk	6	6	73.3
	33	Daily 3 times/wk	6	6	69.7
Schulze et al	166	Daily	6	12	80
Nodular BCC					
Eigentler, et al	45	Daily 3 times/wk	8	8	64†
	45	Daily 3 times/wk	12	8	63†
Huber, et al	15	Daily 3 times/wk	12	12	100
Shumack, et al	21	Daily	12	6	76
	23	Daily 5 times/wk	12	6	70
	20	Daily 3 times/wk	12	6	60
	35	Daily	6	6	71
	31	Twice daily 3 times/wk	6	6	42
	32	Daily 3 times/wk	6	6	59

BCC, basal cell carcinoma.

*Based on histologic clearance.

†Not based on intent-to-treat analysis.

tumor necrosis factor- α , thus stimulating both innate and acquired immunity. A new formulation of imiquimod, 3.75% cream (Zyclara; Graceway Pharmaceuticals, LLC, Bristol, TN) is also approved for the treatment of actinic keratoses on the face and scalp, although this concentration has yet to be studied in nonmelanoma skin cancer.

A number of randomized controlled trials have been conducted to assess the efficacy of imiquimod, 5% cream in the treatment of superficial BCCs. A variety of dosing regimens and treatment durations have been evaluated, with a reported histopathologic clearance rate between 79% and 100% for a once-daily application regimen and 81%-82% for a 5-days-per-week application regimen. A summary is provided in Table 1.

In a small randomized, double-blind pilot study by Beutner et al,²¹ in 35 patients with superficial or nodular BCC, various imiquimod dosing regimens were examined with a treatment duration of up to 16 weeks. Surgical excision and histopathologic analysis were performed at 6 weeks after treatment completion. Patients who were randomized to twice-daily ($n = 7$), once-daily ($n = 4$), and 3 times per week ($n = 4$) application of imiquimod had complete histologic clearance of target tumors compared with a 9% response rate in the vehicle control group. Those patients randomized to twice weekly ($n = 5$) and once weekly ($n = 4$) experienced lower efficacy rates.

Schulze et al²² conducted a randomized, vehicle-controlled, double-blind study of 166 patients evaluating the daily application of imiquimod, 5% cream to superficial

BCCs for a treatment duration of 6 weeks. Analyzing the intent-to-treat dataset, the composite clearance rate was 77% for the imiquimod group and 6% for the vehicle control group ($P < 0.001$). Histopathologic clearance was 80% for the imiquimod group and 6% for the vehicle control group ($P < 0.001$). Approximately 30% of patients in the imiquimod treatment group experienced local skin reactions (erythema, erosions, and scabbing/crusting) versus 1% in the vehicle control group.

Various dosing regimens for the treatment of superficial BCCs with imiquimod, 5% cream were investigated by Geisse et al²³ in a randomized, double-blind, vehicle-controlled study published in 2002. The findings in this study indicated that efficacy was highest for the twice daily dosing regimen with 100% histopathologic clearance after 12 weeks of application with excisions performed 6 weeks posttreatment; however, severe local skin reactions were documented in 3/10 patients, including erythema and scabbing. The complete response rate for once daily application for 12 weeks was 87.1% (27/31) and 80.8% (21/26) for 5 days per week application for 12 weeks. The authors of this study concluded that the once daily and 5 days per week regimen had the most acceptable clearance rates and safety profile.

Similarly, 2 imiquimod dosing regimens for the treatment of superficial BCCs, including a 5-day per week application for 6 weeks (vehicle vs imiquimod) and daily application for 6 weeks (vehicle vs imiquimod) were compared by combining the data from 2 separate, multicenter, randomized, double-blind, vehicle-controlled studies. Lesions were examined

and excised at 12 weeks posttreatment. When an intent-to-treat analysis was undertaken, a statistically significant difference in complete clearance was not seen between the 5 days per week application group (82% histologic clearance, 152/185) and daily application group (79% histologic clearance, 141/179). A greater rate of application site reactions was appreciated, however, with daily application of imiquimod compared with the 5-day per week application ($P = 0.002$). The most commonly reported reactions included itching (26% in daily application group compared with 16% in 5 days per week application group), burning (9% in daily application group compared with 6% in 5 days per week application group), and pain (6% in daily application group and 3% in 5 times per week application group).²⁴

Marks et al²⁵ likewise published a randomized, open-label study evaluating imiquimod application twice daily, once daily, twice daily 3 times per week, and once daily 3 times per week in 99 patients with superficial BCC for a total treatment duration of 6 weeks. Histologic assessment was conducted at 6 weeks posttreatment. When an intent-to-treat analysis was undertaken, a complete response rate of 100% (3/3) was reported in the twice daily application group, compared with 87.9% (29/33) in the once daily application group. This rate dropped to 73.3% (22/30) for patients in the twice daily 3 times per week group and to 69.7% (23/33) in the once daily 3 times per week group. Enrollment in the twice daily application group was limited secondary to reports of application site skin reactions.

Regarding the efficacy of imiquimod in the treatment of nodular BCCs, few randomized controlled trials have been published to date. In general, lower clearance rates have been demonstrated after treatment with imiquimod in cases of nodular BCC given the depth of tumor infiltration. Shumack et al²⁶ published the results of 2 multicenter studies, including a 6 week randomized open-label study and a 12 week randomized, vehicle-controlled, double-blind study evaluating 4 dosing regimens of imiquimod, with histologic assessment conducted at 6 weeks posttreatment. In this study, the highest efficacy was seen with daily application of imiquimod for 12 weeks (76% clearance rate, 16/21), although this was similar to the clearance rate seen with daily application of imiquimod for 6 weeks (71% clearance rate, 25/35). Four patients discontinued treatment because of local skin reactions in the once daily application group. Of note, a twice daily dosing scheme was attempted; however, enrollment of

patients into this arm was discontinued because of the severity of local skin reactions.

A second randomized open-label trial of the use of imiquimod in nodular BCCs compared a 3 times per week application regimen for 8 weeks versus 12 weeks, with histopathologic assessment at 8 weeks posttreatment. Although an intent-to-treat analysis was not performed, a complete histopathological clearance was observed in 58 of 90 (64%) patients, with no statistically significant difference between the 8-week versus 12-week treatment arms.²⁷

Although imiquimod as a monotherapy for nodular BCCs may not be justified on the basis of current data, imiquimod has shown efficacy as an adjunctive treatment after curettage and electrodesiccation of nodular BCCs. In a double-blind, vehicle-controlled study of 20 patients with nodular BCCs, a substantial decrease in the number of patients with evidence of residual tumor was seen after daily application of imiquimod for 1 month after curettage and electrodesiccation (1/10 with residual tumor in treatment group vs 4/10 with residual tumor in vehicle group).²⁸

Sukal and colleagues²⁹ reported 2 cases of recurrent facial nodular BCC after reported clinical clearance with imiquimod therapy. They presented intraoperative frozen sections demonstrating recurrent BCC during Mohs micrographic surgery on these prior treated patients. The tumor was mid-dermis with a Grenz zone like clearance of tumor in the superficial dermis and epidermis. This highlights the limitation a topical may have in penetrating deeply to effectively treat the depth of the tumor. They stress the importance of continued clinical as well as histopathological monitoring of patients who undergo treatment of NMSC with topical therapy and suggest limiting treatment with topical therapy of NMSC to superficial primary nonfacial lesions less than 2 cm.

Imiquimod for Squamous Cell Carcinoma In-Situ

A number of studies have shown efficacy in the treatment of SCCIS with imiquimod, as outlined in Table 2. The authors of a randomized, double-blind, placebo-controlled trial investigating the treatment of biopsy proven SCCIS with daily application of imiquimod for 16 weeks resulted in a 73% (11/15) complete response rate as assessed by histopathologic examination (shave biopsy) at 12 weeks posttreatment.³⁰ Furthermore, in an open-label study by Mackenzie-

Table 2 Select Studies Addressing Imiquimod for SCC³⁰⁻³²

	Sample Size	Dosing Regimen	Treatment Duration	Time of Histologic Assessment, wks	Clearance Rate, %*	Follow-Up Time, mos
In situ						
Pate, et al	5	Daily	16 wks	12	73	9
Mackenzie-Wood et al	16	Daily	16 wks	6	87.5	6
Peris et al	5	Daily 5 times/wk	Up to 16 wks	4	80	31
Invasive						
Peris et al	7	Daily 5 times/wk	Up to 16 wks	4	71.0%	31

SCC, squamous cell carcinoma.

*Based on histologic clearance.

Wood et al³¹ in which 16 patients with SCCIS ≥ 1 cm in diameter were treated with daily application of imiquimod for 16 weeks, a response rate of 87.5% (14 of 16 patients) was documented at 6 weeks posttreatment through incisional biopsy. Of note, 10 patients completed 16 weeks of treatment while 6 patients terminated treatment early because of local skin reaction, including 4 cases of *Staphylococcus aureus* colonization. Finally, Peris et al³² evaluated once daily application of imiquimod for 5 consecutive days a week for up to 16 weeks in 10 patients with 12 cases of squamous cell carcinoma, including 7 invasive SCC lesions, with punch biopsy performed at 4 weeks after treatment discontinuation. In this study, 4 of 5 (80%) patients with SCCIS and 5 of 7 (71.4%) patients with invasive SCCs had complete regression after 8-12 weeks of treatment, with correlation noted between clinical and histopathologic evaluation. No recurrences were noted after a mean follow-up time of 31 months.

Review of Photodynamic Therapy for Nonmelanoma Skin Cancer

In 1999, photodynamic therapy was approved for the treatment of nonhyperkeratotic solar keratoses on the face and scalp as a 20% topical 5-aminolaevulinic acid (ALA), Levulan (DUSA Pharmaceuticals, Wilmington, MA), in combination with a blue light source with 417 nm peak output. Several years later, application of MAL, Metvix (PhotoCure ASA, Oslo, Norway; and Galderma, Paris, France) followed by illumination with a red light source with 630 nm peak output was also approved for the treatment of actinic keratoses. These 2 topical photosensitizers are converted to protoporphyrin IX in the membranes of mitochondria and lysosomes, which upon irradiation with visible light in the 450- to 750-nm wavelength range, generates reactive oxygen species with subsequent apoptosis and damage to target cells. Photodynamic therapy has been increasingly used in several dermatologic conditions, of which the data regarding its efficacy in non-melanoma skin cancer will be critically reviewed below.

In 2007, the International Society for Photodynamic Therapy in Dermatology presented recommendations based on available data at the time of the report. The reported guidelines were made on the quality of clinical trial data, evidence-based results, safety, and tolerability as well as cosmesis and patient satisfaction. The reported guidelines are as follows: Superficial basal cell (including large and multiple lesions) can be effectively and reliably treated with limited side effects and good cosmetic results with PDT. Nodular BCC, of < 2 mm in-depth, has been shown in long-term follow up of 5 years to be effectively treated with MAL-PDT with good cosmetic result. SCCIS or Bowen's disease can also be effectively treated with PDT with good cosmesis.³³

Photodynamic Therapy for Basal Cell Cancer

In general, cure rates for superficial BCCs have ranged from 62% to 91%, with those for nodular BCCs ranging from 50%

to 92%, as summarized in Table 3. This broad range is likely attributable to varied treatment regimens and outcome measures among published studies, thus making meaningful comparisons difficult.

In a prospective, randomized study by Rhodes et al³⁴ comparing surgical excision (5 mm margin) of nodular BCC with MAL-PDT (3-hour incubation, red light 570-670 nm, 75 J cm^2 , 50-200 mW cm^2 , 1-2 cycles), the 5-year complete response rate was 76% in the MAL-PDT group versus 96% for those undergoing surgical excision ($P = 0.01$). However, MAL-PDT led to a more favorable cosmetic outcome, which was noted to be good or excellent in 27 of 31 (87%) of patients with MAL-PDT versus 19 of 35 patients (54%) treated with excision. The efficacy of ALA-PDT (6-hour incubation, frequency doubled Nd:YAG 635 nm, pulse width 100 ns, 60 J cm^2 , 80 \pm 20 mW cm^2 , 1-2 cycles) in the treatment of superficial and nodular BCCs has also been compared with cryosurgery in a prospective randomized trial, with histologic assessment (punch biopsy) at 12 months as the primary end point. They found no statistically significant difference in either treatment modality, with a recurrence rate of 25% (11 of 44) for the ALA-PDT group and 15% (6 of 39) for cryosurgery.

Interestingly, a greater recurrence rate was noted for superficial BCCs (38%, 8/21) compared with nodular BCCs (13%, 3/23).³⁵ Conflicting results were noted in an analysis of 2 multicenter, randomized, double-blind controlled trials in which the authors evaluated the efficacy of MAL-PDT (gentle curettage, 3-hour incubation, broad-spectrum red light 570-670 nm, 75 J/ cm^2 , 50-200 mW/cm^2 , 2 PDT sessions \times 1-2 cycles) versus vehicle cream in the treatment of nodular BCCs, with histopathologic analysis at 6 months. Although a complete response rate of 73% (55/75) was noted for those undergoing MAL-PDT versus 27% (20/75) in the placebo group, the rate was worse in larger lesions (≥ 1 cm in diameter) and in lesions with a depth of > 1 mm.³⁶

Others have also shown that tumor thickness in nodular BCCs correlates with response. Kalka et al found that 67% of nodular BCCs < 2 mm in thickness achieved a complete response after PDT, whereas only 34% of thicker tumors responded.³⁷ Repeated illumination has also been evaluated in a prospective, randomized, controlled trial in which 149 patients with 173 nodular BCCs either received surgical excision (3 mm margin) versus ALA-PDT (debulking with curettage 3 weeks prior, 4-hour incubation, broadband metal halogen light source 585-720 nm, with repeat illumination after 1 hour). With a median follow-up time of 28 months, 2 recurrences were noted in the excision group versus 21 in the ALA-PDT group, resulting in a failure rate of 2.3% for excision and 30.3% for ALA-PDT.³⁸

The authors of a multicenter randomized study investigating MAL-PDT (3-hour incubation, wavelength 570-670 nm, light dose 75 J/cm, 1-3 cycles) versus cryotherapy in the treatment of superficial BCCs found no statistically significant difference in 5-year recurrence rates (20% with cryotherapy vs 22% with MAL-PDT, $P = 0.86$).³⁹ An open-label trial examining MAL-PDT (debulking with curettage, 3-hour incubation, red light 634 nm, 2 treatments separated by

Table 3 Select Studies Addressing PDT for BCC^{35,36,38-41,51,54,74,75}

	Sample Size	Sensitizer	Incubation Time	Light Source	No. of Treatments	Clearance Rate, %	Follow-Up Time
Superficial BCC							
Basset-Seguin et al	103	MAL-PDT	3 h	Red light 570-670 nm	1-3	78%	5 years
Calzavara-Pinton et al	23	ALA-PDT	6-8 h	630 nm	2	86.9%*	2-3 years
Haller et al	26	ALA-PDT	3 h of ALA, then 1 h of EMLA cream	630 nm ± 15 nm	2	4%†	15-45 mo
Morton et al‡	73	ALA-PDT	6 h	630 nm ± 15 nm	1-3	78-86%	34-41 mo
Soler, et al	131‡	MAL-PDT	3-24 h	Halogen 570-670 nm	1-4	91%†	2-4 years
Surrenti, et al	94	MAL-PDT§	3 h	Red light 634 nm ± 3 nm	Up to 8	87.2%†	1 year
Wang et al	21	ALA-PDT	6 h	Nd:YAG 635 nm	1-5	62%	1 year
Nodular BCC							
Calzavara-Pinton et al	30	ALA-PDT	6-8 h	630 nm	4	50%*	2-3 years
Foley et al	75	MAL-PDT§	3 h	Red light 570-670 nm	2-4	73%	3-9 mo
Mosterd et al	83	ALA-PDT§	4 h	Halogen light 585-720 nm (illuminated twice)	1	69.7%†	28 mo
Soler et al	168‡	MAL-PDT§	3-24 h	Halogen 570-670 nm	1-4	89%†	2-4 years
Surrenti et al	24	MAL-PDT§	3 h	Red light 634 nm ± 3 nm	Up to 8	52.5%†	1 year
Thissen, et al	24	ALA-PDT§	6 h	Red light 630-635 nm	1	92%	3 mo
Wang et al	23	ALA-PDT	6 h	Nd:YAG 635 nm	1-5	87%	1 year
Pigmented BCC							
Calzavara-Pinton et al	4	ALA-PDT	6-8 h	630 nm	4	0%*	2-3 years
Unspecified or multiple BCC types							
Morton et al	73	ALA-PDT	6 h	630 nm ± 15 nm	1-3	78-86%	34-41 mo
Soler et al	350	MAL-PDT	3-24 h	Halogen 570-670 nm	1-4	79%†	2-4 years

ALA-PDT, 5-aminolaevulinic acid photodynamic therapy; BCC, basal cell carcinoma; MAL-PDT, methyl-aminolaevulinic acid photodynamic therapy.

*Based on histology at 30 days after treatment or clinical examination at 24-36 months.

†Based on clinical examination only, although Soler, et al confirmed clinically suspicious recurrence with cytology.

‡Only including those with complete clinical response at 3-6 months after treatment.

§With tumor or debulking.

1-week up to maximum of 8 monthly sessions) for the treatment of 94 superficial and 24 nodular BCCs, including 25 recurrent BCCs, resulted in complete clinical and histopathological resolution in 84 of 94 (89.4%) superficial BCCs and 12 of 23 (52.2%) nodular BCCs, with no further efficacy gained with repeat treatments. Recurrence was observed in 2 of 84 (2.4%) superficial BCCs at a mean follow-up of 12 months.⁴⁰

Thisen et al⁴¹ also examined debulking with curettage 3 weeks before treatment with ALA-PDT (6-hour incubation, red light 630-635 nm, 120 J/cm², 100 mW/cm²) in 23 patients with 24 nodular BCCs and found that 22 of 24 (92%) nodular BCCs showed a complete response on clinical and histopathological examination at 3 months after treatment, with good or excellent cosmetic results in the 22 resolved BCCs. It is important to note that a study by Barlow, et al documented a 96% cure rate when treating selected basal cell carcinomas with curettage alone (no electrocautery). The utility of MAL-PDT in the prevention and treatment of BCCs in patients with basal cell nevus syndrome has also been demonstrated, representing an attractive treatment modality for early lesions arising in clinically normal skin.⁴²

In addition to debulking of the tumor via curettage or repeat PDT treatments, techniques by which to improve the efficacy of PDT for BCCs have included adjunctive laser treatment, penetration enhancers, such as dimethylsulfoxide (DMSO), and microdermabrasion. Curettage and DMSO treatment (5-min exposure, 99% solution for lesions on trunk and extremities; 4% DMSO added to ALA for lesions on face and scalp) before ALA-PDT of nodular and superficial BCCs (3-hour incubation, broadband light 550-700 nm) resulted in a complete histologic clearance at 3 years' follow-up in 43 of 53 (81%) treated lesions. A control group was not evaluated.⁴³

Soler et al⁴⁴ incorporated a 15 minute pretreatment with DMSO before ALA treatment of superficial BCCs (3-hour incubation), and compared the efficacy with exposure to either broadband light (570-740 nm) or laser light (630 nm). A complete clinical response at 6 months was noted in 86% of patients treated with laser light compared with 82% treated with broadband light, although this difference was not statistically significant. It has also been shown that microdermabrasion before PDT treatment results in increased erythema at the treatment site, although its effect on efficacy in the treatment of BCCs has not yet been determined.⁴⁵ Er:YAG laser treatment (600-1000 mJ, 7 Hz) before MAL-PDT (3-hour incubation, Aktelite 630 nm, 37 J/cm²) for recurrent nodular BCCs of the head and neck led to a clinical resolution in 98.7% of patients undergoing combined Er:YAG/MAL-PDT treatment versus 94.85% in the MAL-PDT only group versus 91.75% in the Er:YAG laser only group. Of note, this analysis was based on only 194 of 286 patients originally treated.⁴⁶ CO₂ laser (Ultra Pulse CO₂ laser, 150 mJ, 10 Hz, 2-mm collimated beam) followed by MAL-PDT (3-hour incubation, Aktelite LED lamp 631 nm, 37 J/cm², 2 treatments given at a 1-week interval) was performed in 12 patients with 13 nodular BCCs, with all lesions responding clinically and

no recurrences detected at a mean follow-up time of 18 months. Two cases of hypopigmentation were reported.⁴⁷

Photodynamic Therapy for Squamous Cell Cancer In Situ

Although the efficacy of PDT in the treatment of SCCIS has been demonstrated, recurrence rates are in general higher compared with surgical excision, ranging from 7% to 15% in most published studies. Most studies to date present limited data based on clinical rather than histologic clearance. A summary of these studies is provided in Table 4.

In a randomized study comparing treatment of SCCIS with ALA-PDT followed by illumination with either red light (4-hour incubation, 630 nm \pm 15 nm, 125 J/cm², 86 mW/cm²) or green light (4-hour incubation, 540 nm \pm 15 nm, 62.5 J/cm², fluence 86 mW/cm²), 30 of 32 (94%) lesions treated with red light had clinical clearance after 1 to 2 treatments compared with only 21 of 29 (72%) lesions treated with green light ($P = 0.002$). At 1-year follow-up, 7 recurrences were noted in patients having received illumination with green light compared with only 2 recurrences in patients treated with red light.⁴⁸ In an open label trial of 14 patients with 36 lesions of SCCIS treated with ALA-PDT (3- to 6-h incubation 630 nm, 125-250 J/cm², 150 mW/cm²), complete clinical response was seen in 35 of 36 (97%) lesions at 2 months, which decreased to 89% (32 of 36 lesions) at a median follow-up time of 18 months.⁴⁹ In a retrospective study by Fink-Puches et al⁵⁰ 35 superficial SCCs were treated with ALA-PDT (4-h incubation, slide projector—full spectrum or filtered visible light, 50-100 mW/cm²). Complete clinical response after 2-4 weeks post-treatment was noted in 19 of 35 cases (54%). In a median follow-up time of 8 months, 11 of 19 patients developed a recurrence of disease, 5 of 19 remained complete responders, and 3 were lost to follow-up. In treating large diameter (>20 mm) plaques of SCCIS with ALA-PDT (4-h incubation, 630 nm \pm 15 nm, 125 J/cm², 1-3 treatments), 35 of 40 (88%) lesions had complete clinical clearance 6 weeks posttreatment, of which 4 recurred within 1 year.

In a subanalysis of patients with ≥ 3 plaques of SCCIS, 44 of 45 (98%) plaques cleared, with 4 recurrences within 1 year.⁵¹ Varma et al⁵² also investigated ALA-PDT (4-h incubation, 630 nm, 105-168 mW/cm², 105 J/cm²) in the treatment of SCCIS and found clinical clearance in 44 of 50 (88%) lesions after 2 treatment sessions, although this abruptly dropped to 69% at 1-year follow-up, with most recurrences occurring within 6 months. An 82% (27/33) clinical clearance rate at 1 year was observed in a study by Salim et al¹⁹ in which 33 lesions of SCCIS were treated with ALA-PDT (4-hour incubation, red light 630 nm \pm 15 nm, 100 J/cm², 50-90 mW/cm²). A case report demonstrating efficacy of ALA-PDT (4-hour incubation, red light 635 nm) in the treatment of subungual SCCIS has also been published, with no evidence of clinical recurrence after 30 months.⁵³

As mentioned previously in this review, treatment of SCCIS with MAL-PDT (3-hour incubation, red light 570-670 nm, 75 J/cm²) versus cryotherapy or 5-FU in a randomized,

Table 4 Select Studies Addressing PDT for SCC^{48,52,54}

Sample Size	Sensitizer	Incubation Time, h	Light Source	No. of Treatments	Clearance Rate*	Follow-Up Time
SCC in situ						
Cairnduff et al	ALA-PDT	2-4	630 nm	1	89%	18 mo
Calzavara-Pinton et al	ALA-PDT	6-8	630 nm	1-3	100%†	2-3 years
Fink-Puches et al	ALA-PDT	4	Lamp	1	23%	8 mo
Morton et al	ALA-PDT	4	Red light 630 ± 15 nm	1-2	0.88	1 year
Morton et al	ALA-PDT	4	Green light 540 ± 15 nm	1-2	0.48	1 year
Varma et al	ALA-PDT	4	630 nm ± 15 nm	1-3	78-89%	1 year
Superficial BCC						
Calzavara-Pinton et al	ALA-PDT	4	Waldmann PDT 1200 (630 nm)	1-4	33%	1 year
Nodular BCC						
Calzavara-Pinton et al	ALA-PDT	6-8	630 nm	1-3	83.3%†	2-3 years
Keratoacanthoma						
Calzavara-Pinton et al	ALA-PDT	6-8	630 nm	2-6	33.3%†	2-3 years
Calzavara-Pinton et al	ALA-PDT	6-8	630 nm	2	100%†	2-3 years

ALA-PDT, 5-aminolaevulinic acid photodynamic therapy; SCC, squamous cell carcinoma.

*Based on clinical examination.

†Based either on histology at 30 days after treatment or clinical examination at 24-36 months.

placebo controlled study yielded a complete clinical response 3 months post-treatment in 103 of 111 (93%) patients treated with MAL-PDT versus 73 of 85 (86%) in the cryotherapy group versus 24 of 29 (83%) patients treated with 5-FU. Recurrence rates at 1 year were 15% in MAL-PDT group, versus 21% in the cryotherapy group, versus 17% in 5-FU group.²⁰

Photodynamic Therapy for Invasive Squamous Cell Cancer

There is limited published data at this time to support the implementation of photodynamic therapy as a treatment modality for invasive squamous cell cancer. As with nodular BCCs, the depth of penetration of ALA or MAL as well as limited depth of penetration of illumination sources into tissue may prohibit destruction of these lesions.

In an open label study by Calzavara-Pinton et al which included 6 nodular SCCs treated with ALA-PDT (6- to 8-hour incubation, 630 nm argon-pumped dye laser, 60-80 J/cm², treatments were repeated every other day for 4 treatments), histopathologic resolution was observed in only 2 of 6 (33%) lesions at a median follow-up time of 29 months.⁵⁴ The noted high recurrence rates and metastatic potential of SCC has limited further investigation to date.

Photodynamic Therapy for Extramammary Paget's Disease

Much of the data regarding the use of photodynamic therapy for extramammary Paget's disease is derived from case reports and case series. Mohs micrographic surgery currently produces the lowest recurrence rates compared with standard surgical techniques. In fact, local recurrence is quite common with surgical excision, ranging from 31% to 61% in some studies, thus adjunctive treatments may be needed to control disease.⁵⁵

A retrospective case series published by Housel et al⁵⁶ included 5 patients with 16 lesions of anogenital extramammary Paget's disease who were treated with ALA-PDT (18-24-h incubation, red light 632 nm), with use of adjuvant iontophoresis and fractionated light delivery through use of a red lamp (590-720 nm). At 6 months' follow-up, 8 of 16 (50%) lesions demonstrated a complete response, 3 of 16 (19%) lesions had a partial response, and 5 of 16 (31%) lesions had a marginal response. Three lesions that initially had a complete response developed recurrences within 10 months. Included in this study were also patients treated with intravenous porfimer sodium PDT, which resulted in clinical clearance in 7 of 9 lesions at a median follow-up time of 62 months.

A second series by Raspagliesi et al⁵⁷ in which 7 patients with recurrent vulvar extramammary Paget's disease underwent MAL-PDT (3-hour incubation, Aktlite red light 620 nm, 37 J/cm², treatment every 3 weeks for 3 treatments) found a clinical complete response in 4 of 7 patients, although this was confirmed histologically in only 2 patients.

Intralesional Photodynamic Therapy for Nonmelanoma Skin Cancer

It has been postulated that insufficient penetration of ALA may account for the lower efficacy rates encountered in nodular BCCs undergoing PDT treatment. Intralesional injection of ALA rather than topical application has been suggested as a means to increase tumor response to this treatment modality. In support of this, intracutaneous injection of ALA has demonstrated a greater level of protoporphyrin IX fluorescence in porcine skin compared with topical application.⁵⁸ Furthermore, de Blois et al⁵⁹ have developed a stable composition of ALA (concentration of 0.1-5.0% and a pH of 5.0) that they conclude would be suitable for intratumoral injection.

A current study by the authors of this review paper addresses the effectiveness of non-coherent blue light in intralesional PDT for the treatment of BCC.⁶⁰ A prospective study of 20 BCCs treated with injection of 20% aminolevulinic acid, incubated for 1 hour, and exposed to noncoherent blue light has been initiated. When clinical clearance was not achieved at 8 weeks, the BCC was treated a second time. Evaluations at 16 weeks, 1 year, and 2 years after PDT include punch biopsies of the treatment sites. To date, all 20 BCCs have been evaluated at 16 weeks, showing recurrence at 2 sites on histology. For those 18 sites still negative at 16 weeks, 13 have been reevaluated at 1 year, revealing an additional 4 sites of histologic recurrence. Five have returned for their 2 year examination and shown recurrence at 1 more site. An example of a complete clinical clearance at the 2-year follow-up visit is demonstrated in Fig. 1. Although the recurrence rate may increase with the pending 1 and 2 year follow-up visits, the overall recurrence rate, including non-responders, is presently 35% (7 of 20 sites). Notably, physicians graded cosmetic outcome as good-to-excellent in 2/3 or more of the treatment sites at all follow-up examinations. No unusual adverse event has been appreciated.⁶⁰

Adverse Effects of Photodynamic Therapy

During exposure of the photosensitizer to light, pain, burning, and/or pruritus have been noted, with peak effects usually experienced within the first few minutes of treatment. It has been hypothesized that these local skin reactions are secondary to nerve stimulation and/or tissue damage by reactive oxygen species.⁶¹ A number of studies have shown that pain is greater using ALA compared with MAL, possibly reflecting greater protoporphyrin IX fluorescence.^{62,63} Although analgesia is not typically required, one could consider pretreatment with topical lidocaine and Prilocaine (EMLA; AstraZeneca, Luton, UK) or the use of cooling fans/sprays during treatment. After exposure to light, photosensitivity continues to increase, thus patients should strictly avoid exposure to light for at least 48 hours to prevent phototoxic reactions. Edema and erythema can also occur, with the potential for crusting and erosions. Complete healing can be expected within 1-6 weeks. Although the incidence of scarring is rare, pigmentary alter-

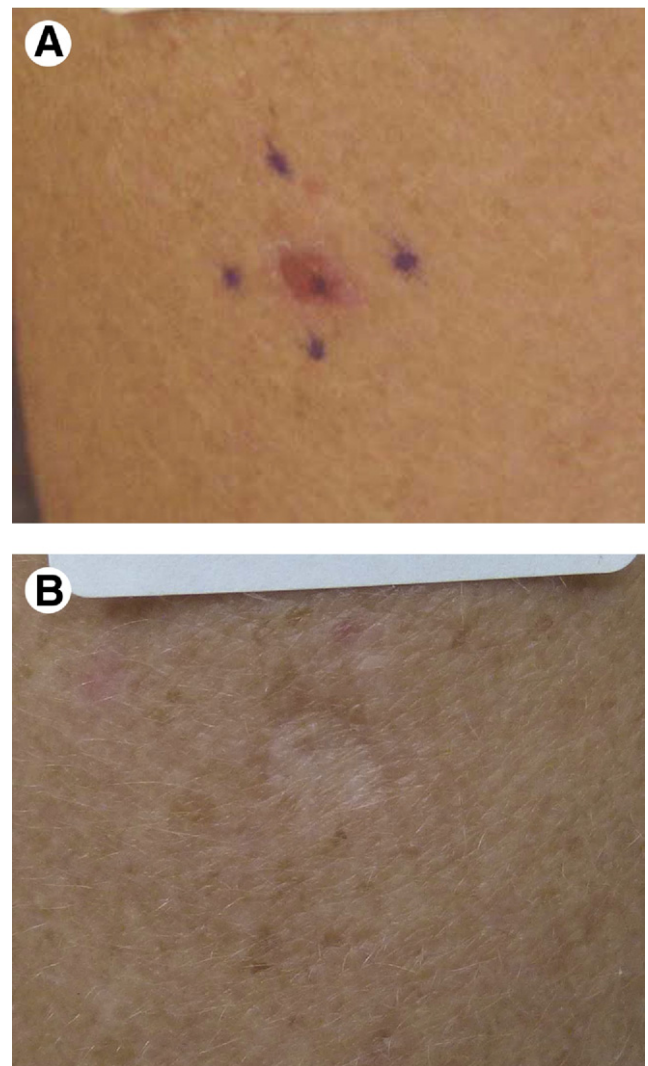


Figure 1 Shown here is a biopsy proven basal cell carcinoma (A) before treatment and (B) 2 years after treatment with intralesional PDT. Treatment consisted of injection of 20% aminolevulinic acid, 1-hour incubation, and exposure to noncoherent blue light.

ation has been noted in 1% of patients.⁶⁴ Most cases of postinflammatory hypo- or hyperpigmentation resolve within a few months.

Other Nonsurgical Treatment Modalities for Nonmelanoma Skin Cancer

Peels

Phenol peels have also been examined in the treatment of SCCIS. Kaminaka et al,⁶⁵ in a study in which 14 patients with SCCIS underwent treatment with phenol peels, found 10 of 14 patients experienced a complete clinical and histopathologic response, with only 1 case recurring in 1-year follow-up.

Lasers

A number of case reports have been published documenting efficacy of CO₂ laser treatment of both BCC and SCCIS. One of the earlier reports examining efficacy of CO₂ laser for treatment of NSMC was Humphreys et al.⁶⁶ They histologically examined 30 superficial NSMCs (17 BCCs, 13 SCC) treated with pulsed CO₂ laser (500 mJ, 204 W, 3-mm spot size, 2-3 passes). They noted greater clearance with 3 passes when treating BCCs. Three patients with basal cell nevus syndrome were successfully treated with a pulsed CO₂ laser (500 mJ, 5 W, 3-mm spot size, 3 to 4 passes) with confirmation demonstrated by Mohs micrographic surgery of a representative lesion, with no recurrences at 18-months follow-up.⁶⁷ Iyer et al.⁶⁸ examined treatment of 61 biopsy proven superficial and nodular BCCs treated with a pulsed CO₂ laser (pulse energy of 300-500 mJ, spot size 3 mm, 10 Hz, 2-8 passes). Patients were followed from 15 to 85 months with clinical recurrence noted in only 2 cases. They report anecdotally favorable cosmesis. Horlock, et al histologically examined effects of CO₂ laser of 51 BCCs, including superficial, nodular and infiltrative, and documented a 100% cure rate for all superficial BCCs. They note this occurred when ablation to middermis was achieved.⁶⁹ In a small case series of 3 lesions of SCCIS, CO₂ laser treatment (500 mJ, 3-mm spot size) followed by diode laser treatment (60 J/cm², 9 mm × 9 mm spot size, 30 ms pulse duration) resulted in clinical clearance of all lesions with a 4-month follow-up time.⁷⁰ The fairly favorable documented clearance rates and ability to limit peripheral tissue damage with small spot size and pulse energy makes this a reasonable treatment modality.

More recently, pulsed dye laser has been evaluated for efficacy in the treatment of BCC. Shah and colleagues⁷¹ theorize that dependency of tumor growth on stromal tissue and vasculature explains the reduction in tumor growth with this treatment option. The trial of pulsed dye laser (15 J/cm², 3-ms pulse duration, 7-mm spot size, 4 treatments every 2-4 weeks) on biopsy-proven BCCs showed that 11 of 12 BCCs, 1.5 cm or less in size, had complete histologic clearance.

Wasserman and colleagues⁷² presented the treatment of 13 BCCs (with long pulsed alexandrite laser: 3-ms pulse duration, 8-mm spot size, 100 J/cm²), of which 10 underwent a single treatment and 3 underwent 4 treatments. Of those undergoing 4 treatments, all 3 lesions showed complete histologic clearance. Of the 10 lesions undergoing 1 treatment, 4 had complete histologic clearance. Although both pulsed-dye (595 nm) and alexandrite (755 nm) lasers may be preferentially absorbed by vascular structures, the extremely high settings used in both the Tannous and the Wasserman studies create an ablative like tissue response which may play a significant role in the noted tumor clearance.

Conclusions

Millions of NMSCs are treated in the United States annually. An urgent need for alternative and preventive treatments is needed, especially for those patients who are poor surgical candidates or those prone to numerous NMSCs. Although

not as efficacious as Mohs micrographic surgery, alternative strategies may be well suited in some instances. Various degrees of efficacy have been found with topical retinoids, 5-FU, imiquimod, photodynamic therapy, chemical peels, and a variety of lasers. The future will likely bring optimized treatment regimens and new technologies that may further improve the success rate against these cancers.

References

- Rogers HW, Weinstock MA, Harris AR, et al: Incidence estimate of nonmelanoma skin cancer in the United States. *Arch Dermatol* 146: 283-287, 2010
- Bordea C, Wojnarowska F, Millard PR, et al: Skin cancers in renal-transplant recipients occur more frequently than previously recognized in a temperate climate. *Transplantation* 77:574-579, 2004
- Carroll RP, Ramsay HM, Fryer AA, et al: Incidence and prediction of nonmelanoma skin cancer post-renal transplantation: A prospective study in Queensland, Australia. *Am J Kidney Dis* 41:676-683, 2003
- Ramsay HM, Fryer AA, Hawley CM, et al: Non-melanoma skin cancer risk in the Queensland renal transplant population. *Br J Dermatol* 147: 950-956, 2002
- Wisgerhof HC, Edelbroek JR, de Fijter JW, et al: Trends of skin diseases in organ-transplant recipients transplanted between 1966 and 2006: A cohort study with follow-up between 1994 and 2006. *Br J Dermatol* 162:390-396, 2010
- Chen JG, Fleischer AB Jr, Smith ED, et al: Cost of nonmelanoma skin cancer treatment in the United States. *Dermatol Surg* 27:1035-1038, 2001
- Bickers DR, Lim HW, Margolis D, et al: The burden of skin diseases: 2004 a joint project of the American Academy of Dermatology association and the Society for Investigative Dermatology. *J Am Acad Dermatol* 55:490-500, 2006
- Leibovitch I, Huilgol SC, Selva D, et al: Cutaneous squamous cell carcinoma treated with Mohs micrographic surgery in Australia I. Experience over 10 years. *J Am Acad Dermatol* 53:253-260, 2005
- Nguyen TH, Ho DQ: Nonmelanoma skin cancer. *Curr Treat Options Oncol Jun* 3:193-203, 2002
- Thissen MR, Neumann MH, Schouten LJ: A systematic review of treatment modalities for primary basal cell carcinomas. *Arch Dermatol* 135: 1177-1183, 1999
- Smeets NW, Kuijpers DI, Nelemans P, et al: Mohs' micrographic surgery for treatment of basal cell carcinoma of the face—Results of a retrospective study and review of the literature. *Br J Dermatol* 151:141-147, 2004
- Tull S, Nunley K, Sengelmann R: Nonsurgical treatment modalities for primary cutaneous malignancies. *Dermatol Surg* 34:859-872, 2008
- Marmur ES, Schmults CD, Goldberg DJ: A review of laser and photodynamic therapy for the treatment of nonmelanoma skin cancer. *Dermatol Surg* 30:264-271, 2004
- Peris K, Fargnoli MC, Chimenti S: Preliminary observations on the use of topical tazarotene to treat basal-cell carcinoma. *N Engl J Med* 341: 1767-1768, 1999
- Bardazzi F, Bianchi F, Parente G, et al: A pilot study on the use of topical tazarotene to treat squamous cell carcinoma in situ. *J Am Acad Dermatol* 52:1102-1104, 2005
- Romagosa R, Saap L, Givens M, et al: A pilot study to evaluate the treatment of basal cell carcinoma with 5-fluorouracil using phosphatidyl choline as a transepidermal carrier. *Dermatol Surg* 26:338-340, 2000
- Gross K, Kircik L, Kricorian G: 5% 5-Fluorouracil cream for the treatment of small superficial basal cell carcinoma: Efficacy, tolerability, cosmetic outcome, and patient satisfaction. *Dermatol Surg* 33:433-439, 2007; discussion: 440
- Bargman H, Hochman J: Topical treatment of Bowen's disease with 5-fluorouracil. *J Cutan Med Surg* 7:101-105, 2003
- Salim A, Leman JA, McColl JH, et al: Randomized comparison of pho-

- todynamic therapy with topical 5-fluorouracil in Bowen's disease. *Br J Dermatol* 148:539-543, 2003
20. Morton C, Horn M, Leman J, et al: Comparison of topical methyl aminolevulinate photodynamic therapy with cryotherapy or fluorouracil for treatment of squamous cell carcinoma in situ: Results of a multicenter randomized trial. *Arch Dermatol* Jun 142:729-735, 2006
 21. Beutner KR, Geisse JK, Helman D, et al: Therapeutic response of basal cell carcinoma to the immune response modifier imiquimod 5% cream. *J Am Acad Dermatol* 41:1002-1007, 1999
 22. Schulze HJ, Cribier B, Requena L, et al: Imiquimod 5% cream for the treatment of superficial basal cell carcinoma: Results from a randomized vehicle-controlled phase III study in Europe. *Br J Dermatol* 152: 939-947, 2005
 23. Geisse JK, Rich P, Pandya A, et al: Imiquimod 5% cream for the treatment of superficial basal cell carcinoma: A double-blind, randomized, vehicle-controlled study. *J Am Acad Dermatol* 47:390-398, 2002
 24. Geisse J, Caro I, Lindholm J, et al: Imiquimod 5% cream for the treatment of superficial basal cell carcinoma: Results from two phase III, randomized, vehicle-controlled studies. *J Am Acad Dermatol* 50:722-733, 2004
 25. Marks R, Gebauer K, Shumack S, et al: Imiquimod 5% cream in the treatment of superficial basal cell carcinoma: Results of a multicenter 6-week dose-response trial. *J Am Acad Dermatol* 44:807-813, 2001
 26. Shumack S, Robinson J, Kossard S, et al: Efficacy of topical 5% imiquimod cream for the treatment of nodular basal cell carcinoma: Comparison of dosing regimens. *Arch Dermatol* 138:1165-1171, 2002
 27. Eigentler TK, Kamin A, Weide BM, et al: A phase III, randomized, open label study to evaluate the safety and efficacy of imiquimod 5% cream applied thrice weekly for 8 and 12 weeks in the treatment of low-risk nodular basal cell carcinoma. *J Am Acad Dermatol* 57:616-621, 2007
 28. Spencer JM: Pilot study of imiquimod 5% cream as adjunctive therapy to curettage and electrodesiccation for nodular basal cell carcinoma. *Dermatol Surg* 32:63-69, 2006
 29. Sukal SA, Mahlberg MJ, Brightman L, et al: What lies beneath? A lesson for the clinician. Intraoperative frozen section appearance of persistent basal cell carcinoma after apparent cure with imiquimod 5% cream. *Dermatol Surg* 35:1831-1834, 2009
 30. Patel GK, Goodwin R, Chawla M, et al: Imiquimod 5% cream monotherapy for cutaneous squamous cell carcinoma in situ (Bowen's disease): A randomized, double-blind, placebo-controlled trial. *J Am Acad Dermatol* 54:1025-1032, 2006
 31. Mackenzie-Wood A, Kossard S, de Launey J, et al: Imiquimod 5% cream in the treatment of Bowen's disease. *J Am Acad Dermatol* 44: 462-470, 2001
 32. Peris K, Micantonio T, Fargnoli MC, et al: Imiquimod 5% cream in the treatment of Bowen's disease and invasive squamous cell carcinoma. *J Am Acad Dermatol* 55:324-327, 2006
 33. Braathen LR, Szeimies RM, Basset-Seguín N, et al: Guidelines on the Use of Photodynamic Therapy for Nonmelanoma Skin Cancer: An International Consensus. International Society for Photodynamic Therapy in Dermatology, 2005. *J Am Acad Dermatol* 56:125-143, 2007
 34. Rhodes LE, de Rie MA, Leifsdottir R, et al: Five-year follow-up of a randomized, prospective trial of topical methyl aminolevulinate photodynamic therapy vs surgery for nodular basal cell carcinoma. *Arch Dermatol* 143:1131-1136, 2007
 35. Wang I, Bendsoe N, Klinteberg CA, et al: Photodynamic therapy vs. cryosurgery of basal cell carcinomas: Results of a phase III clinical trial. *Br J Dermatol* 144:832-840, 2001
 36. Foley P, Freeman M, Menter A, et al: Photodynamic therapy with methyl aminolevulinate for primary nodular basal cell carcinoma: Results of two randomized studies. *Int J Dermatol* 48:1236-1245, 2009
 37. Kalka K, Merk H, Mukhtar H: Photodynamic therapy in dermatology. *J Am Acad Dermatol* 42:389-413, 2000; quiz: 414-386
 38. Mosterd K, Thissen MR, Nelemans P, et al: Fractionated 5-aminolaevulinic acid-photodynamic therapy vs. surgical excision in the treatment of nodular basal cell carcinoma: Results of a randomized controlled trial. *Br J Dermatol* 159:864-870, 2008
 39. Basset-Seguín N, Ibbotson SH, Emtestam L, et al: Topical methyl aminolaevulinate photodynamic therapy versus cryotherapy for superficial basal cell carcinoma: A 5 year randomized trial. *Eur J Dermatol* 18:547-553, 2008
 40. Surrenti T, De Angelis L, Di Cesare A, et al: Efficacy of photodynamic therapy with methyl aminolevulinate in the treatment of superficial and nodular basal cell carcinoma: An open-label trial. *Eur J Dermatol* 17: 412-415, 2007
 41. Thissen MR, Schroeter CA, Neumann HA: Photodynamic therapy with delta-aminolaevulinic acid for nodular basal cell carcinomas using a prior debulking technique. *Br J Dermatol* 142:338-339, 2000
 42. Gilchrist BA, Brightman LA, Thiele JJ, et al: Photodynamic therapy for patients with Basal cell nevus syndrome. *Dermatol Surg* 35:1576-1581, 2009
 43. Christensen E, Skogvoll E, Viset T, et al: Photodynamic therapy with 5-aminolaevulinic acid, dimethylsulfoxide and curettage in basal cell carcinoma: A 6-year clinical and histological follow-up. *J Eur Acad Dermatol Venereol* 23:58-66, 2009
 44. Soler AM, Angell-Petersen E, Warloe T, et al: Photodynamic therapy of superficial basal cell carcinoma with 5-aminolaevulinic acid with dimethylsulfoxide and ethylenediaminetetraacetic acid: A comparison of two light sources. *Photochem Photobiol* Jun 71:724-729, 2000
 45. Katz BE, Truong S, Maiwald DC, et al: Efficacy of microdermabrasion preceding ALA application in reducing the incubation time of ALA in laser PDT. *J Drugs Dermatol* 6:140-142, 2007
 46. Smucler R, Vlk M: Combination of Er: YAG laser and photodynamic therapy in the treatment of nodular basal cell carcinoma. *Lasers Surg Med* 40:153-158, 2008
 47. Whitaker IS, Shokrollahi K, James W, et al: Combined CO(2) laser with photodynamic therapy for the treatment of nodular basal cell carcinomas. *Ann Plast Surg* 59:484-488, 2007
 48. Morton CA, Whitehurst C, Moore JV, et al: Comparison of red and green light in the treatment of Bowen's disease by photodynamic therapy. *Br J Dermatol* 143:767-772, 2000
 49. Cairnduff F, Stringer MR, Hudson EJ, et al: Superficial photodynamic therapy with topical 5-aminolaevulinic acid for superficial primary and secondary skin cancer. *Br J Cancer* 69:605-608, 1994
 50. Fink-Puches R, Soyer HP, Hofer A, et al: Long-term follow-up and histological changes of superficial non-melanoma skin cancers treated with topical delta-aminolaevulinic acid photodynamic therapy. *Arch Dermatol* 134:821-826, 1998
 51. Morton CA, Whitehurst C, McColl JH, et al: Photodynamic therapy for large or multiple patches of Bowen disease and basal cell carcinoma. *Arch Dermatol* 137:319-324, 2001
 52. Varma S, Wilson H, Kurwa HA, et al: Bowen's disease, solar keratoses and superficial basal cell carcinomas treated by photodynamic therapy using a large-field incoherent light source. *Br J Dermatol* 144:567-574, 2001
 53. Usmani N, Stables GI, Telfer NR, et al: Subungual Bowen's disease treated by topical aminolaevulinic acid-photodynamic therapy. *J Am Acad Dermatol* 53:S273-S276, 2005 (suppl 1)
 54. Calzavara-Pinton PG: Repetitive photodynamic therapy with topical delta-aminolaevulinic acid as an appropriate approach to the routine treatment of superficial non-melanoma skin tumours. *J Photochem Photobiol B Biol* 29:53-57, 1995
 55. Shieh S, Dee AS, Cheney RT, et al: Photodynamic therapy for the treatment of extramammary Paget's disease. *Br J Dermatol* 146:1000-1005, 2002
 56. Housel JP, Izikson L, Zeitouni NC: Noninvasive extramammary Paget's disease treated with photodynamic therapy: Case series from the Roswell Park Cancer Institute. *Dermatol Surg* 36:1718-1724, 2010
 57. Raspagliesi F, Fontanelli R, Rossi G, et al: Photodynamic therapy using a methyl ester of 5-aminolaevulinic acid in recurrent Paget's disease of the vulva: A pilot study. *Gynecol Oncol* 103:581-586, 2006
 58. Thissen MR, de Blois MW, Robinson DJ, et al: PpIX fluorescence kinetics and increased skin damage after intracutaneous injection of 5-aminolaevulinic acid and repeated illumination. *J Invest Dermatol* 118:239-245, 2002
 59. de Blois AW, Grouls RJ, Ackerman EW, et al: Development of a stable solution of 5-aminolaevulinic acid for intracutaneous injection in photodynamic therapy. *Lasers Med Sci* 17:208-215, 2002

60. Robert Anolik, Elliot T. Weiss, Christopher Hunzeker, et al. Investigation of the effectiveness of non-coherent blue light in intralesional photodynamic therapy of basal cell carcinoma. American society for laser medicine and surgery annual meeting. Grapevine, Texas, 2011.
61. Morton CA, McKenna KE, Rhodes LE: Guidelines for topical photodynamic therapy: Update. *Br J Dermatol* 159:1245-1266, 2008
62. Kuijpers DI, Thissen MR, Thissen CA, et al: Similar effectiveness of methyl aminolevulinate and 5-aminolevulinate in topical photodynamic therapy for nodular basal cell carcinoma. *J Drugs Dermatol* 5:642-645, 2006
63. Moloney FJ, Collins P: Randomized, double-blind, prospective study to compare topical 5-aminolaevulinic acid methylester with topical 5-aminolaevulinic acid photodynamic therapy for extensive scalp actinic keratosis. *Br J Dermatol* 157:87-91, 2007
64. Moseley H, Ibbotson S, Woods J, et al: Clinical and research applications of photodynamic therapy in dermatology: Experience of the Scottish PDT Centre. *Lasers Surg Med* 38:403-416, 2006
65. Kaminaka C, Yamamoto Y, Yonei N, et al: Phenol peels as a novel therapeutic approach for actinic keratosis and Bowen disease: Prospective pilot trial with assessment of clinical, histologic, and immunohistochemical correlations. *J Am Acad Dermatol* 60:615-625, 2009
66. Humphreys TR, Malhotra R, Scharf MJ, et al: Treatment of superficial basal cell carcinoma and squamous cell carcinoma in situ with a high-energy pulsed carbon dioxide laser. *Arch Dermatol* 134:1247-1252, 1998
67. Nouri K, Chang A, Trent JT, et al: 2 used for the successful treatment of basal cell carcinomas found in patients with basal cell nevus syndrome. *Dermatol Surg* 28:287-290, 2002
68. Iyer S, Bowes L, Kricorian G, et al: Treatment of basal cell carcinoma with the pulsed carbon dioxide laser: A retrospective analysis. *Dermatol Surg* 30:1214-1218, 2004
69. Horlock N, Grobbelaar AO, Gault DT: Can the carbon dioxide laser completely ablate basal cell carcinomas? A histological study. *Br J Plast Surg* 53:286-293, 2000
70. Fader DJ, Lowe L: Concomitant use of a high-energy pulsed CO2 laser and a long-pulsed (810 nm) diode laser for squamous cell carcinoma in situ. *Dermatol Surg* 28:97-99, 2002; discussion: 100
71. Shah SM, Konnikov N, Duncan LM, et al: The effect of 595 nm pulsed dye laser on superficial and nodular basal cell carcinomas. *Lasers Surg Med* 41:417-422, 2009
72. Wasserman DI, Tannous Z, Monheit GD: A prospective pilot study of the 755nm alexandrite laser on basal cell carcinomas, 2010 American College of Mohs Surgery Annual Meeting
73. Huber A, Huber JD, Skinner RB Jr, et al: Topical imiquimod treatment for nodular basal cell carcinomas: An open-label series. *Dermatol Surg* 30:429-430, 2004
74. Haller JC, Cairnduff F, Slack G, et al: Routine double treatments of superficial basal cell carcinomas using aminolaevulinic acid-based photodynamic therapy. *Br J Dermatol* 143:1270-1275, 2000
75. Soler AM, Warloe T, Berner A, et al: A follow-up study of recurrence and cosmesis in completely responding superficial and nodular basal cell carcinomas treated with methyl 5-aminolaevulinic acid-based photodynamic therapy alone and with prior curettage. *Br J Dermatol* 145:467-471, 2001